

# Traitement chirurgical des sténoses carotidiennes. Technique et *Résultats*

Michel Bartoli

Service de chirurgie vasculaire  
Hôpital de la Timone - Marseille



**Sténoses carotidiennes responsables  
de 10-20% des AVC**

# **Chirurgie carotidienne**

**USA**  
*Rutherford 2003*

**170'000**

**FRANCE**  
*ATIH 2017*

**17'268**

# Définition du TCMM

**Taux Cumulé de Morbidité - Mortalité**

*= Total des AVC et décès  
au 30<sup>ème</sup> jour postopératoire*

**= Risque de la chir. carotidienne**

# LE CHEMIN PARCOURU

TCMM

## Série Historique

1977 Easton JD

21,1%

## Séries Actuelles

1995 NASCET

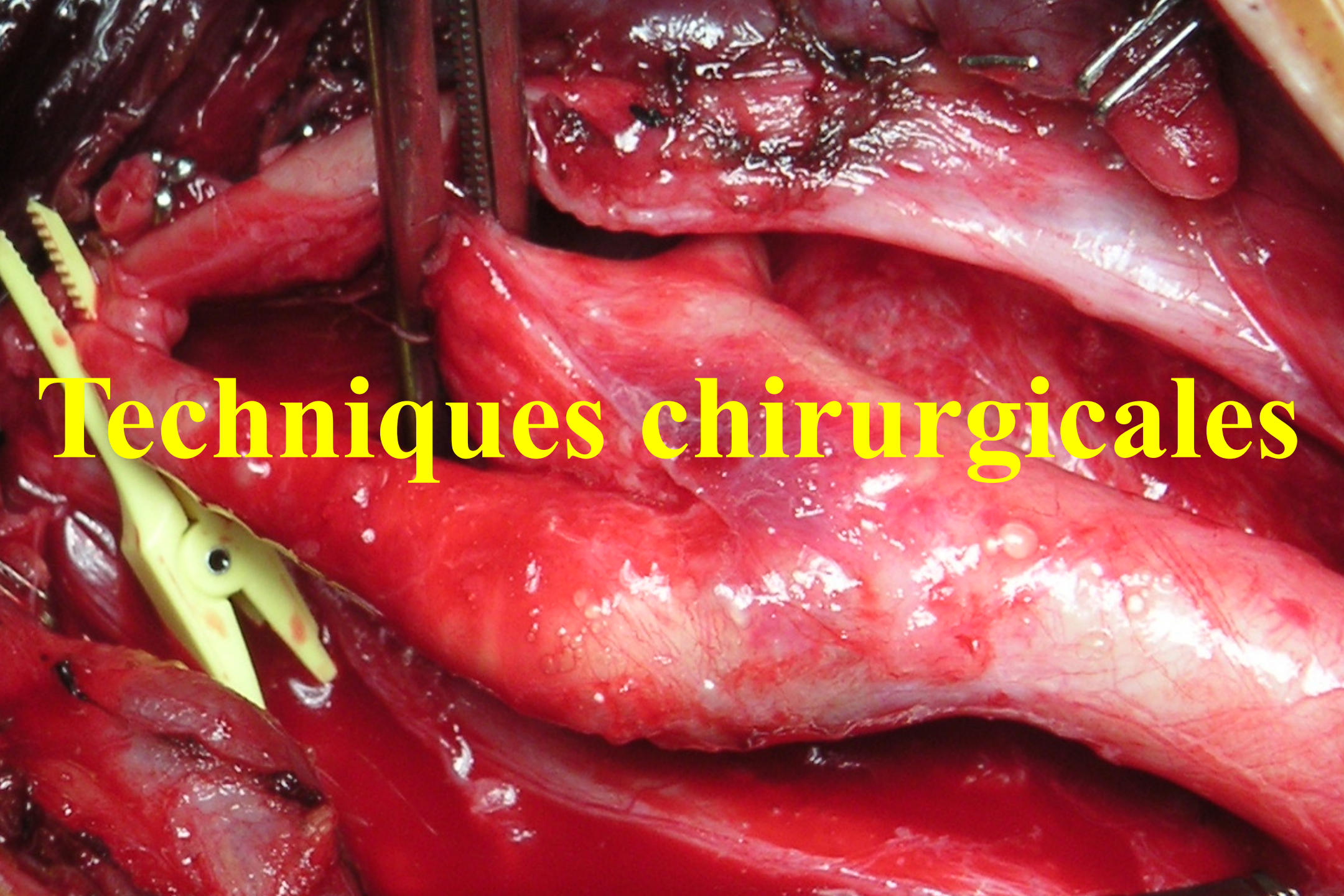
6,5%

2006 EVA 3S (sympt.)

3,9%

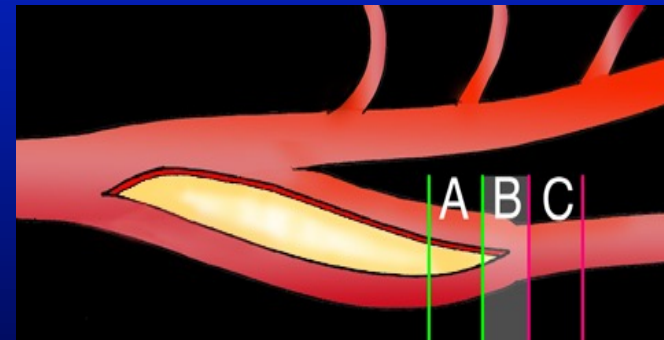
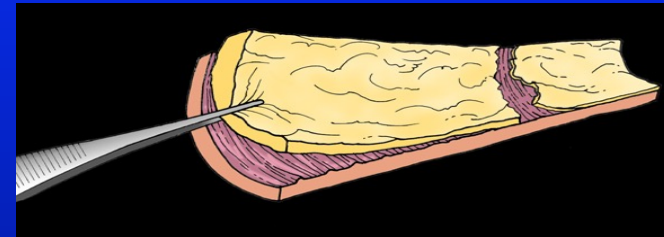
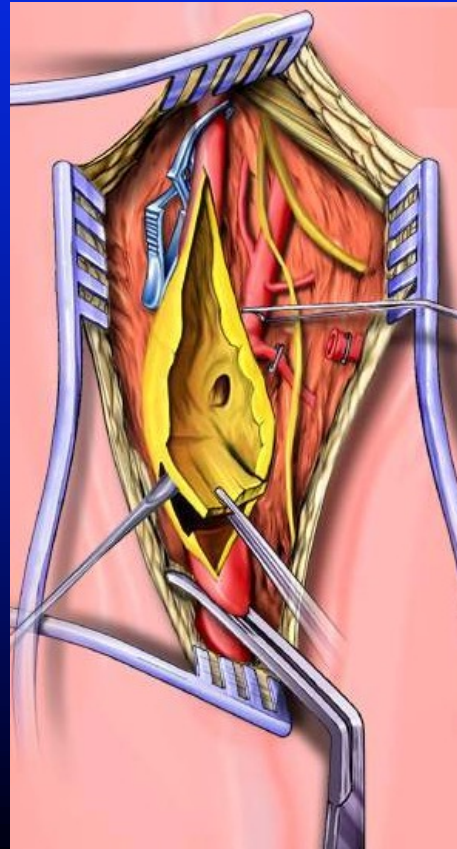
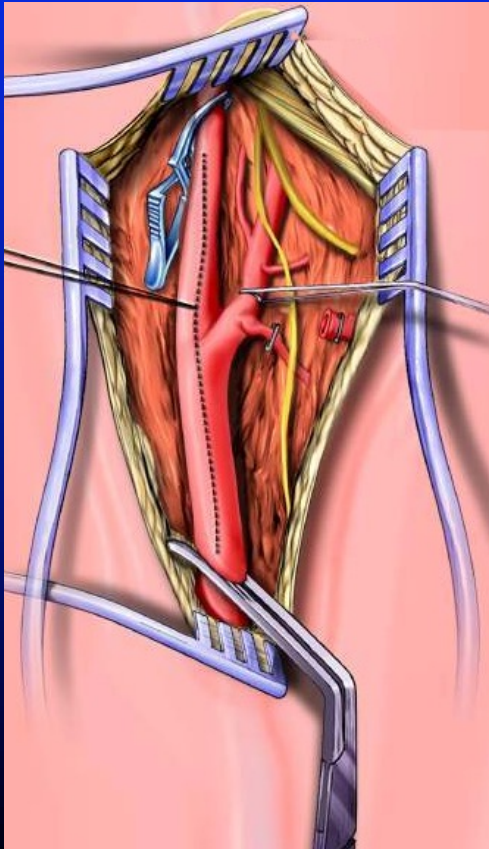
2016 CREST (asympto)

1,7%



# Techniques chirurgicales

# Endartériectomie Ouverte

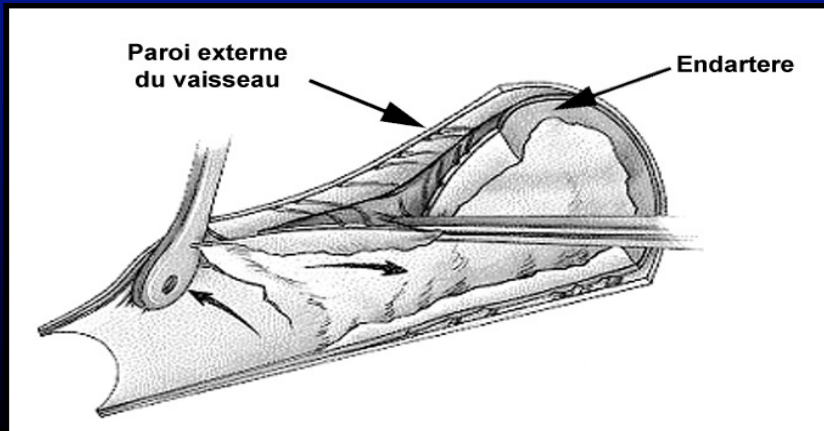
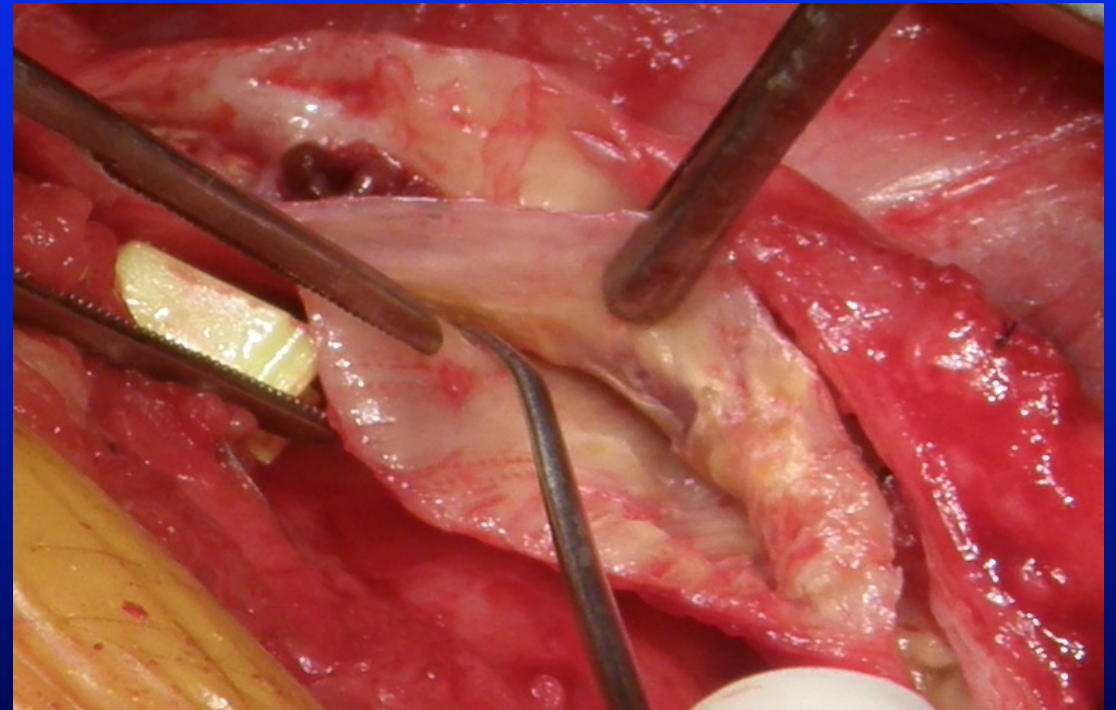
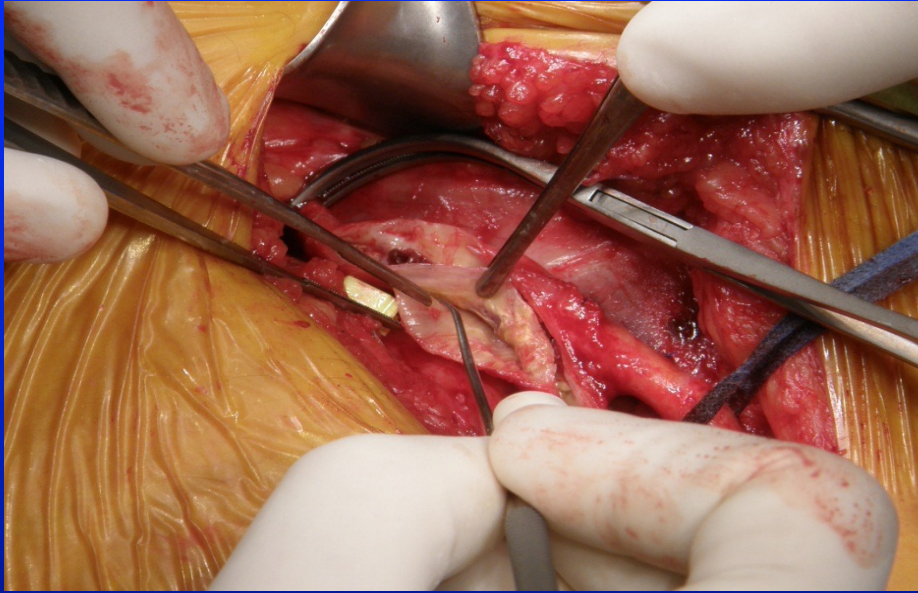


A: Sécurité

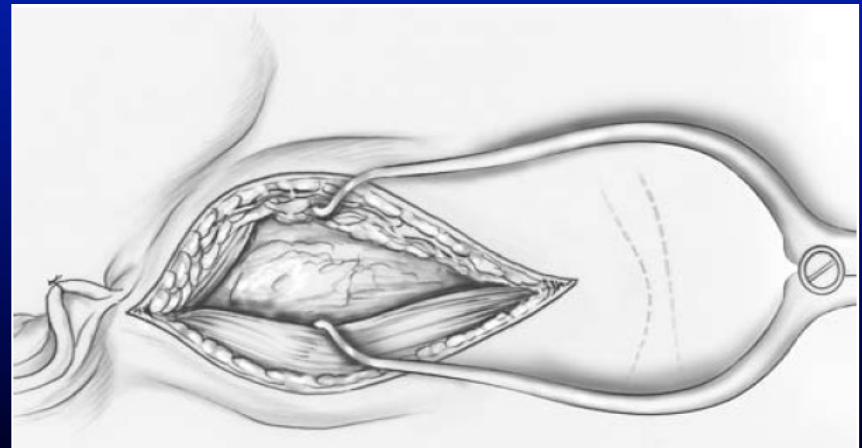
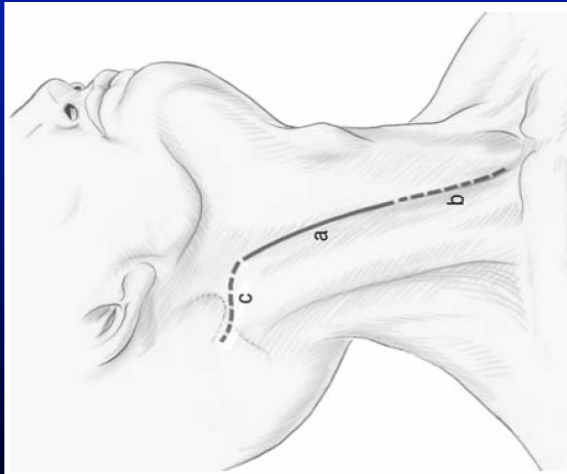
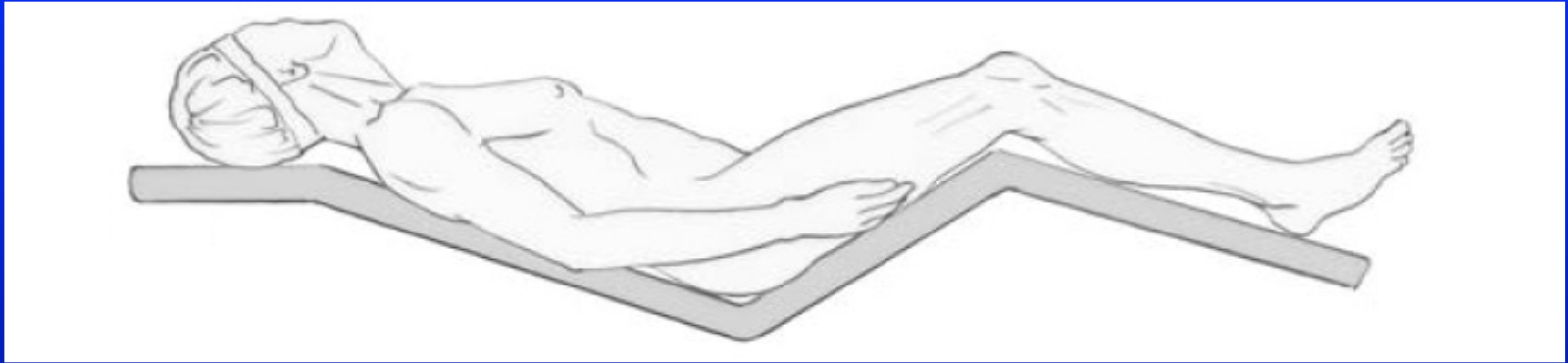
B: Sécurité moyenne

C: Insécurité

# Endartérectomie

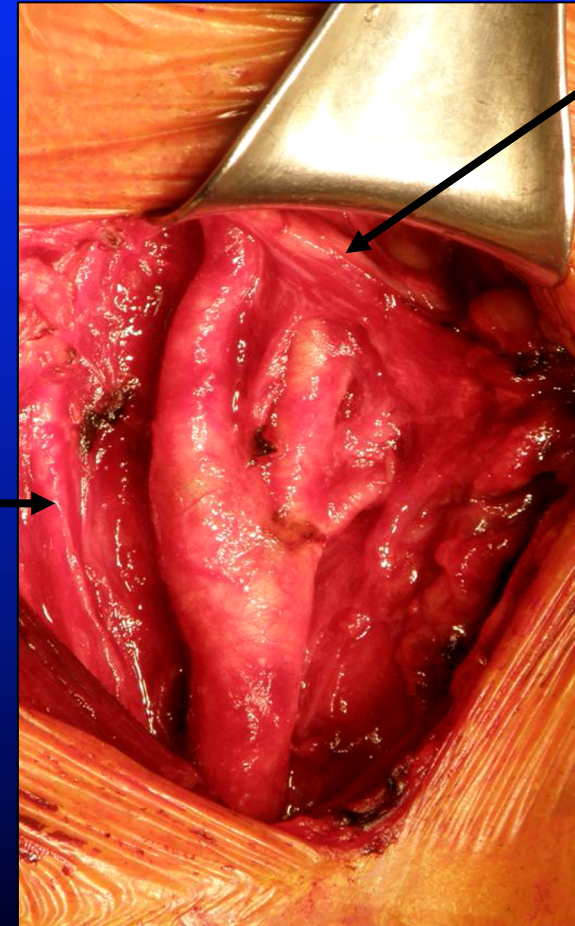
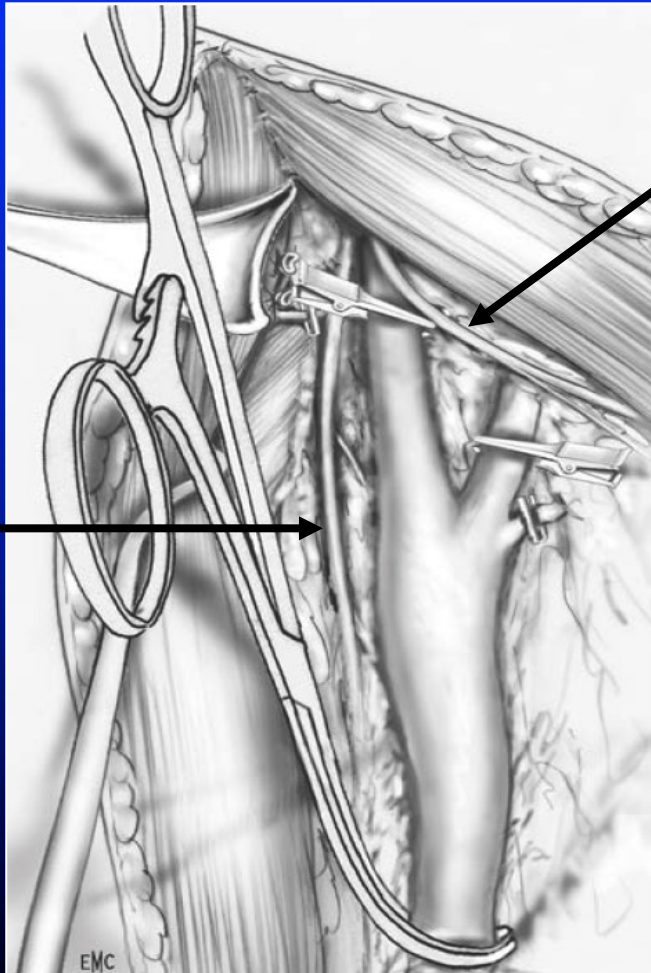


# La Chirurgie

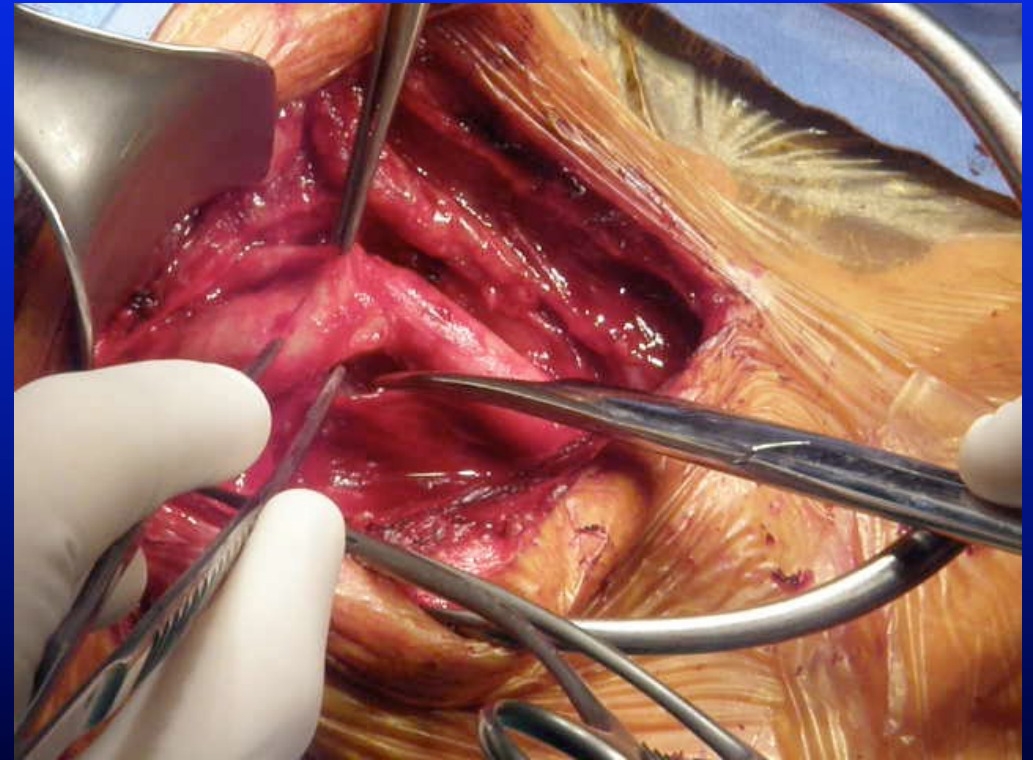
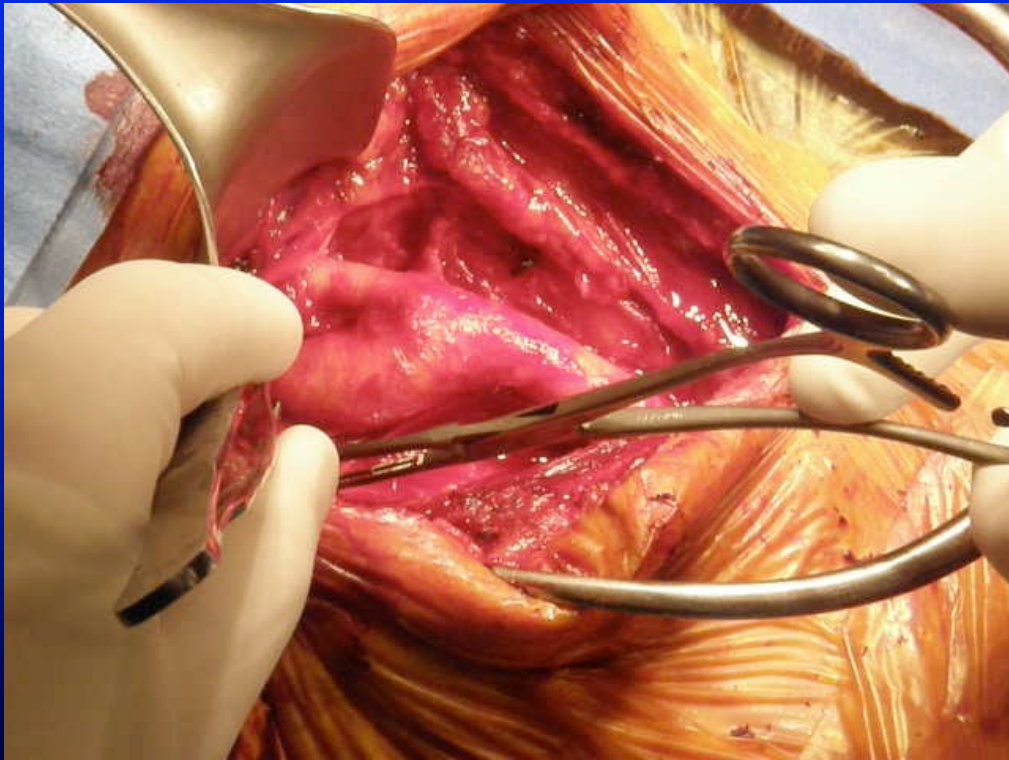




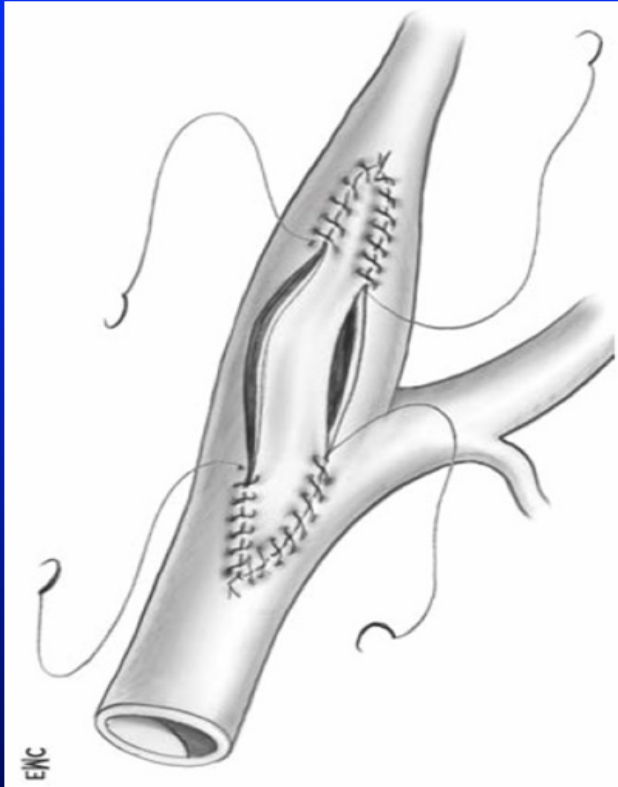
# La Chirurgie



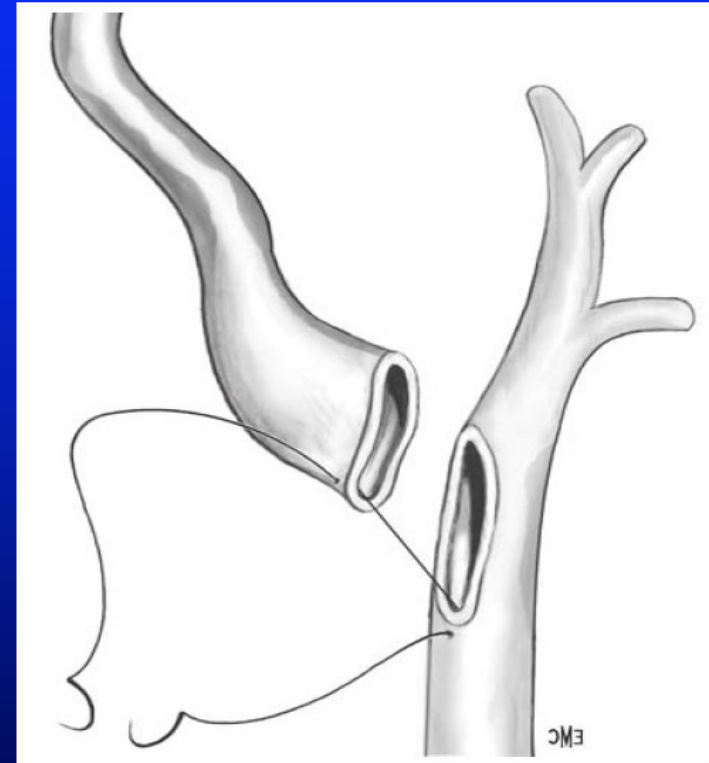
# Dissection du Bulbe



# La Chirurgie: Techniques

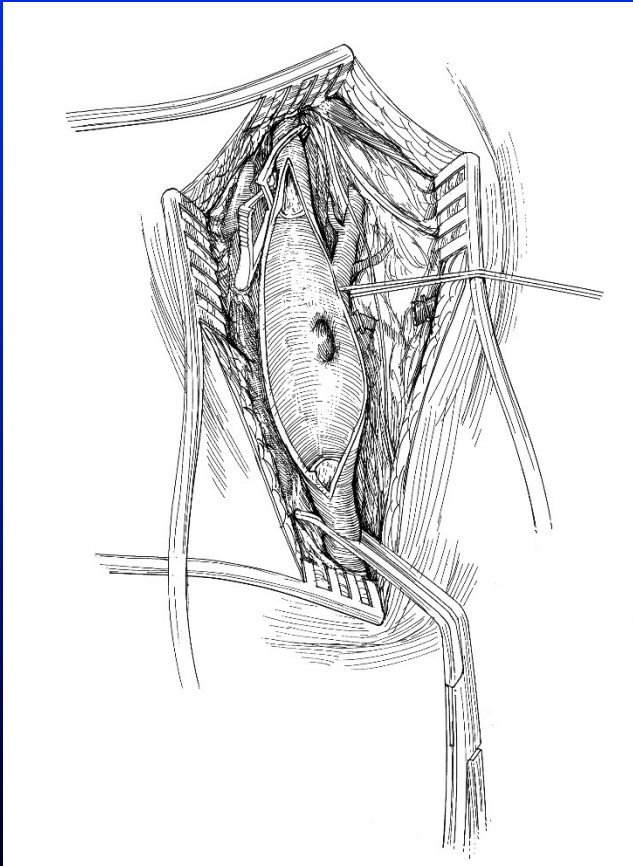


Le Patch

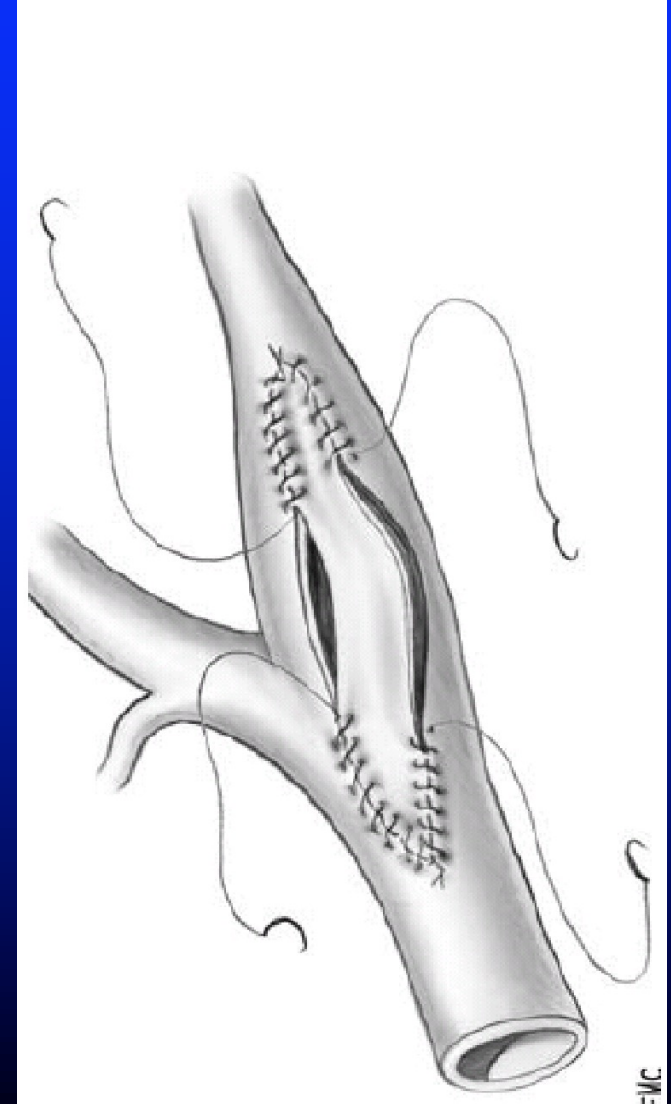


L'Éversion

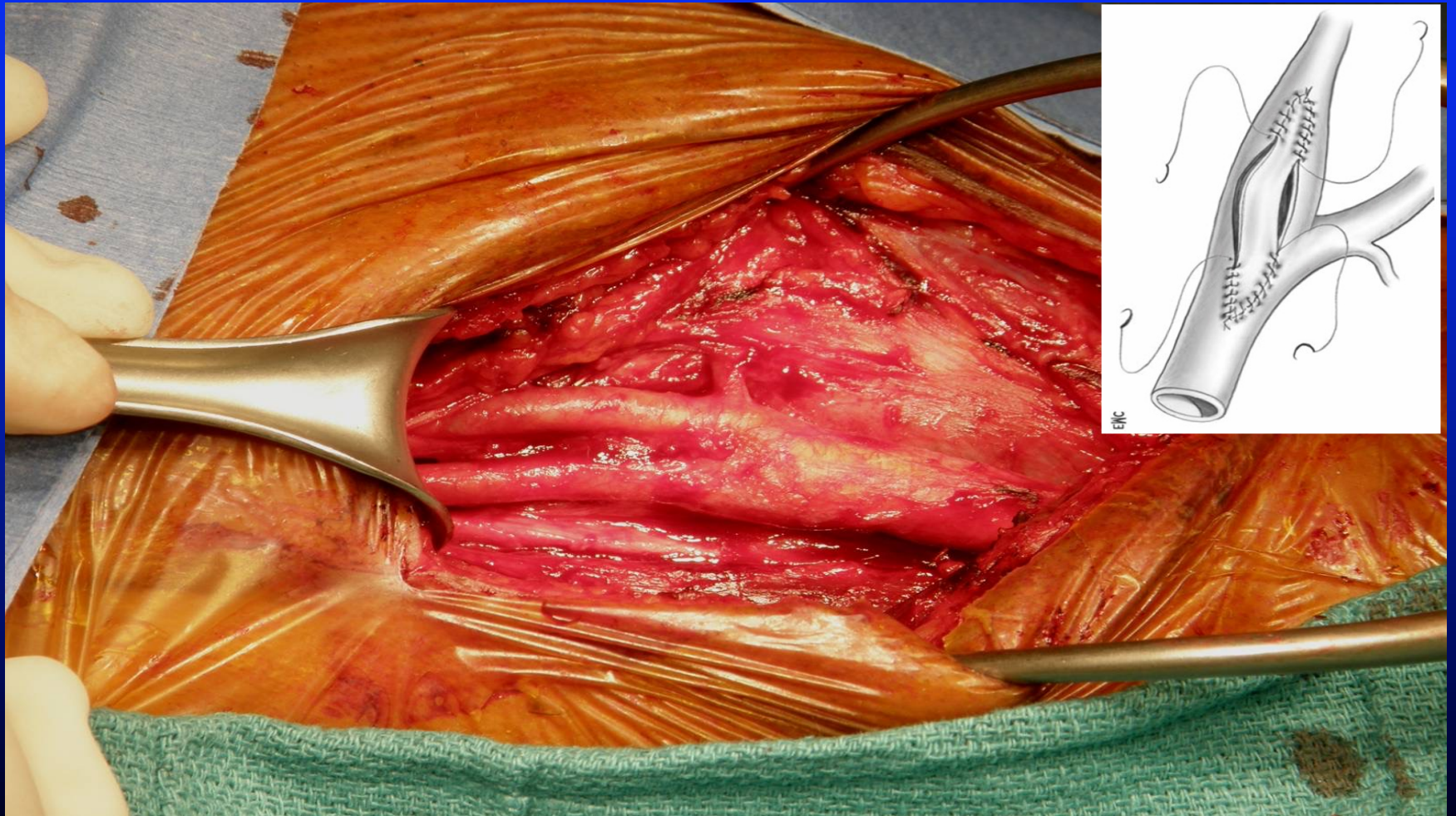
# Fermeture sur Patch



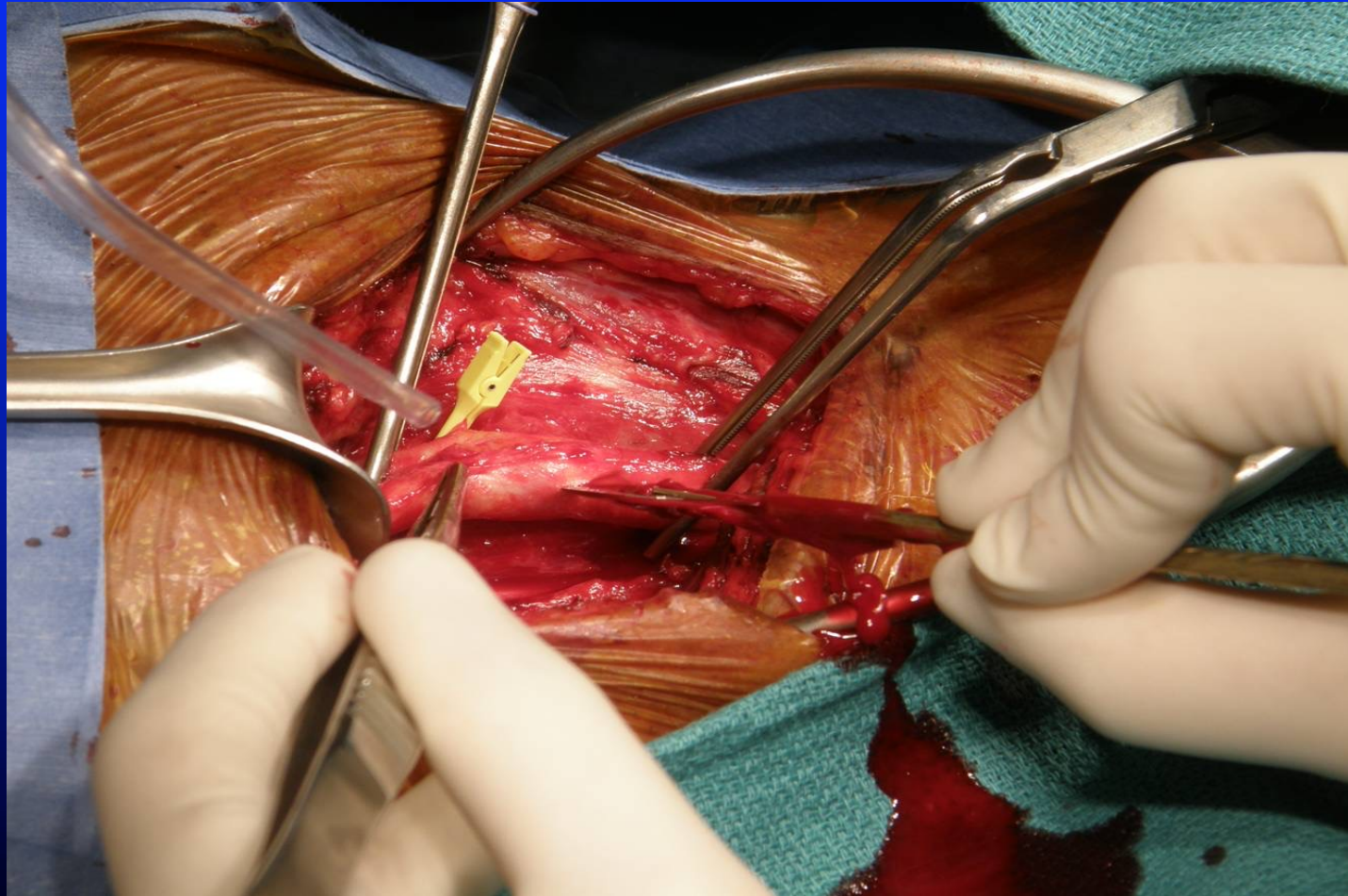
- Veine
- PTFE
- Dacron
- Polyuréthane



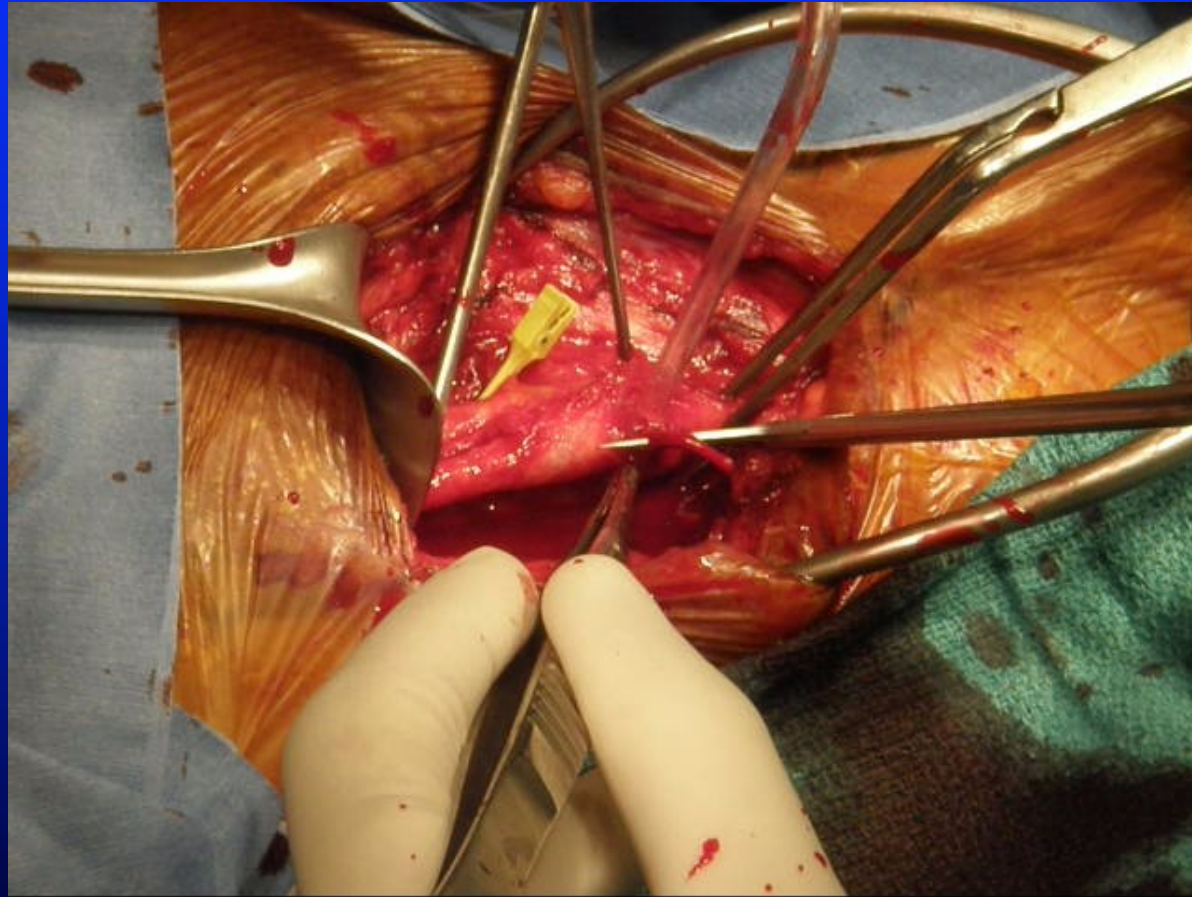
# La Chirurgie: Le Patch



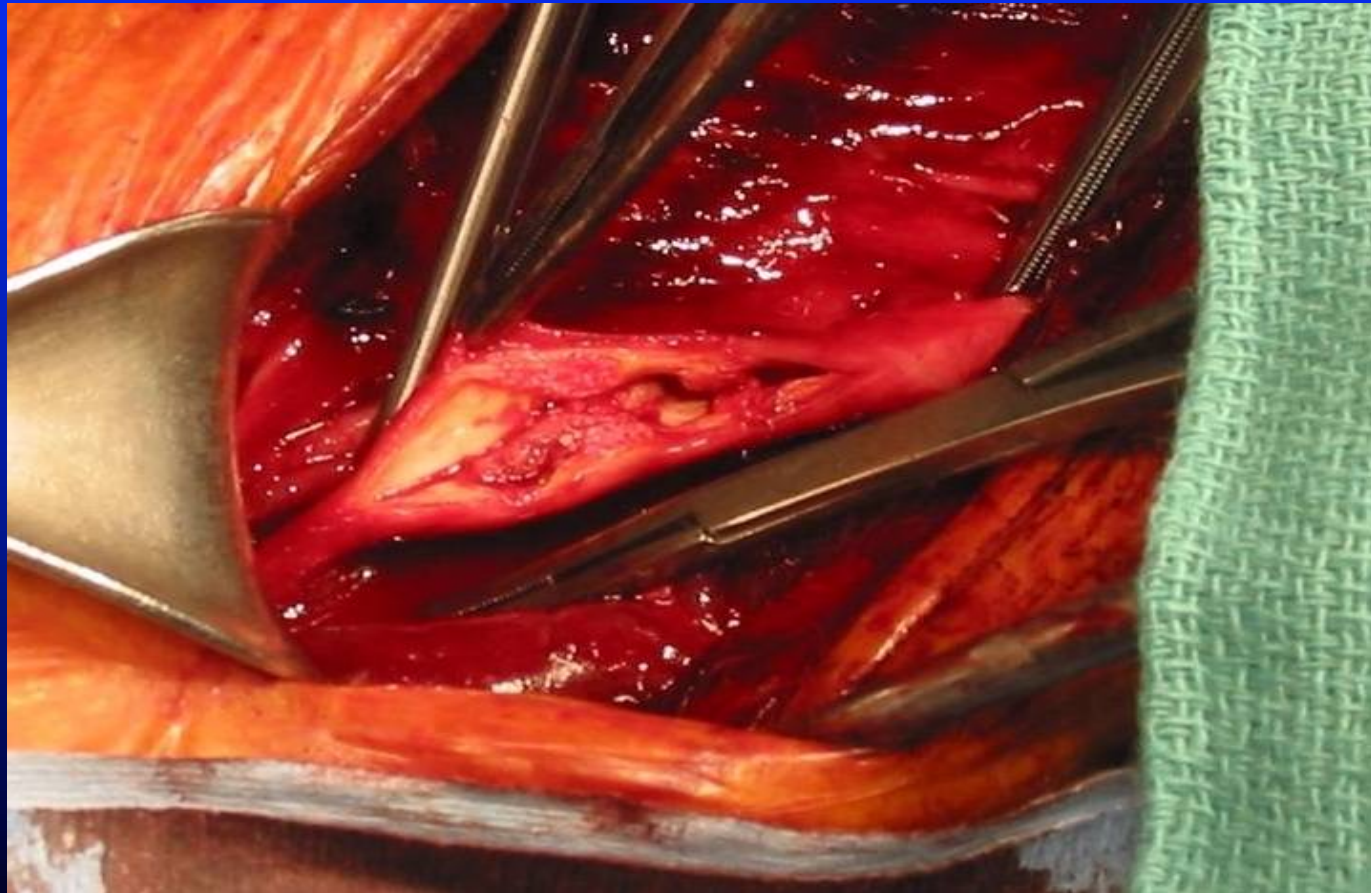
# La Chirurgie: Le Patch



# La Chirurgie: Le Patch

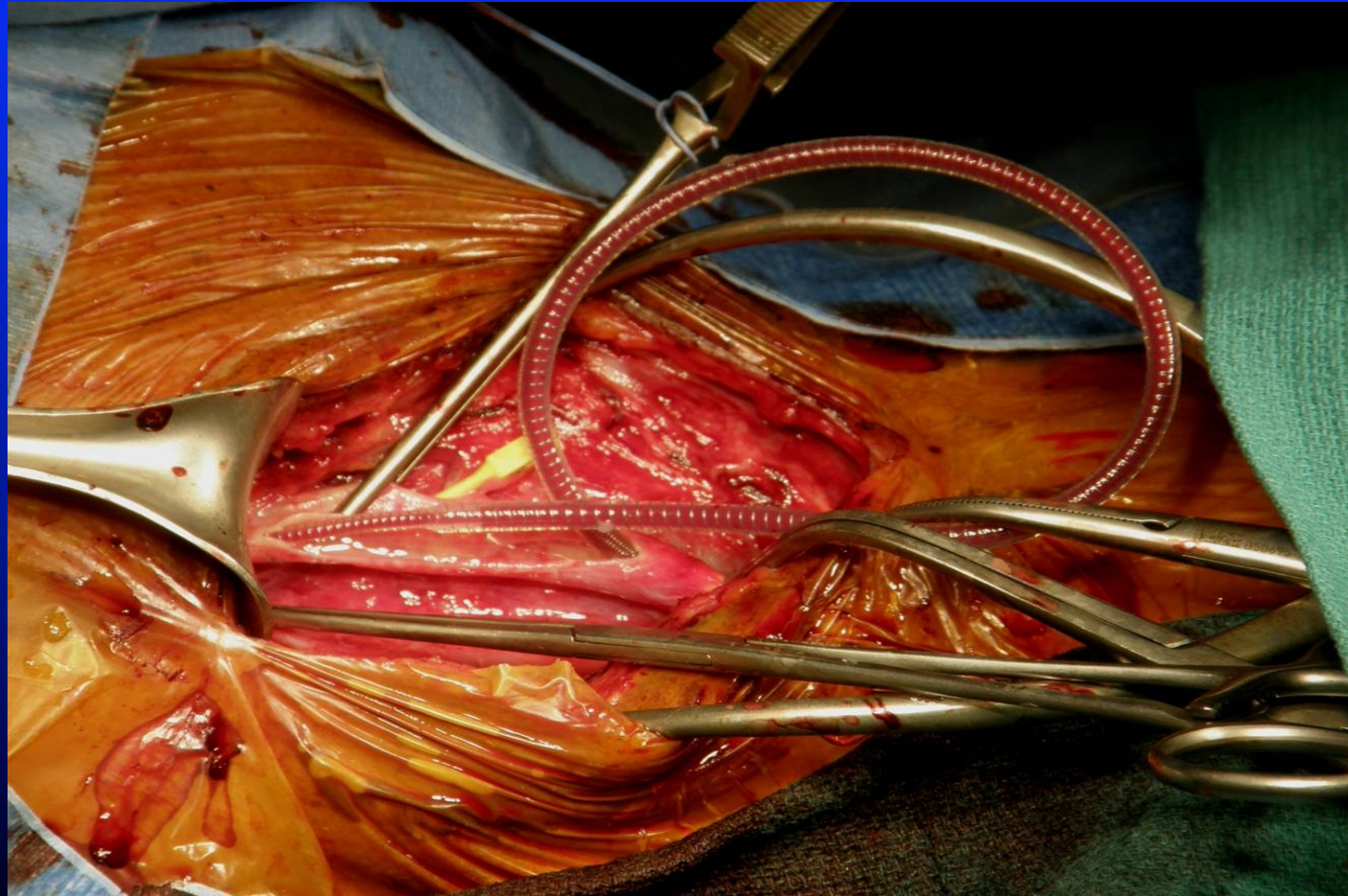


# La Chirurgie: Le Patch

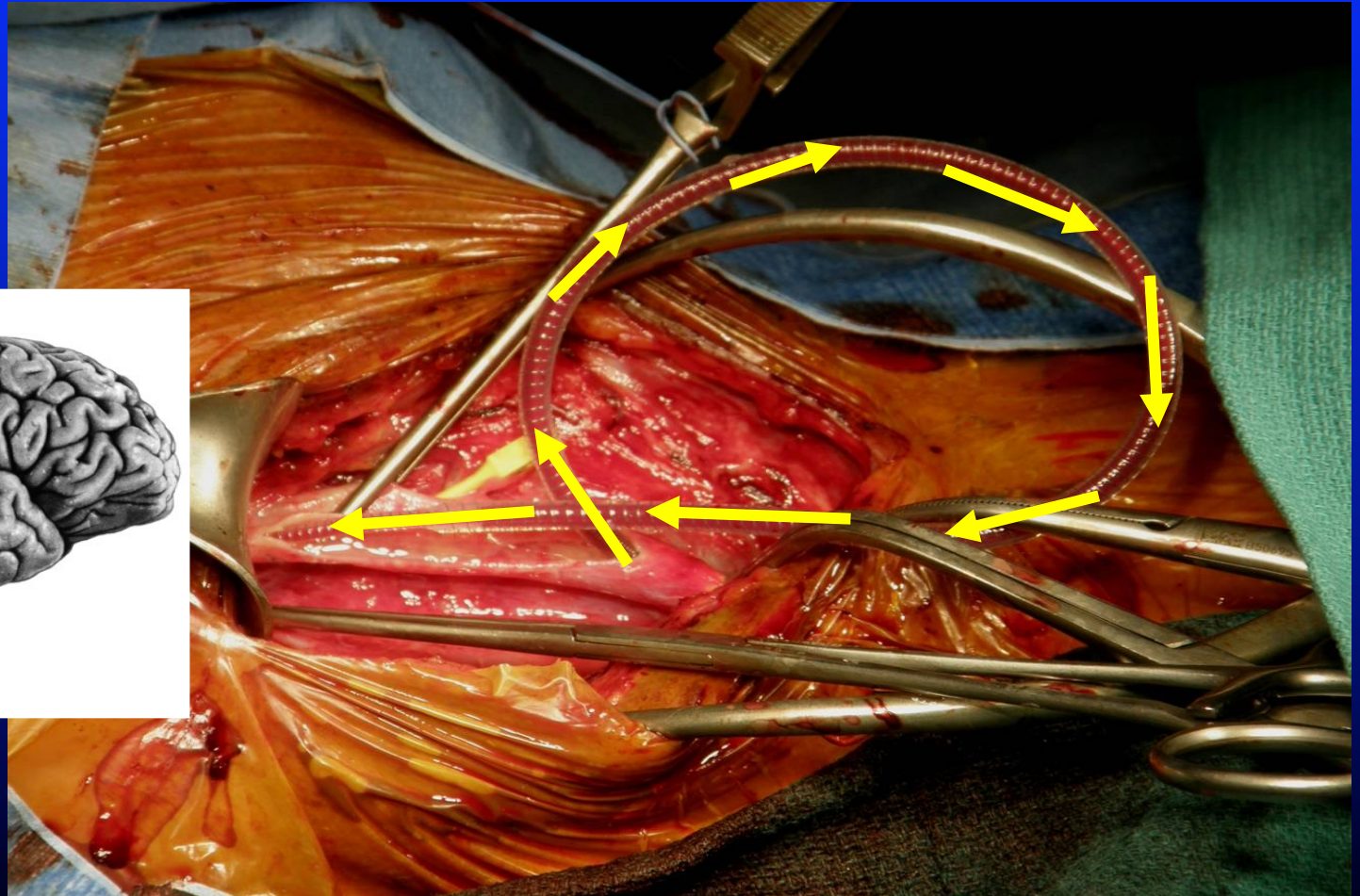
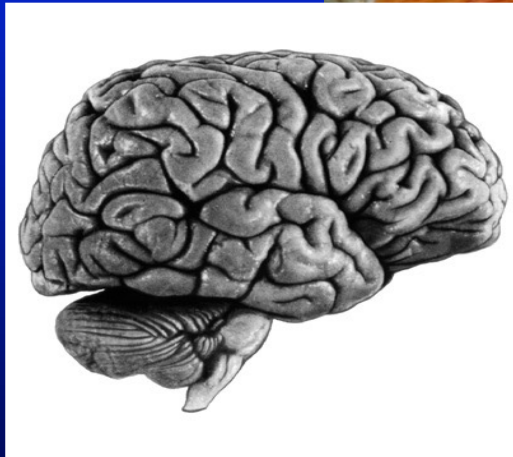



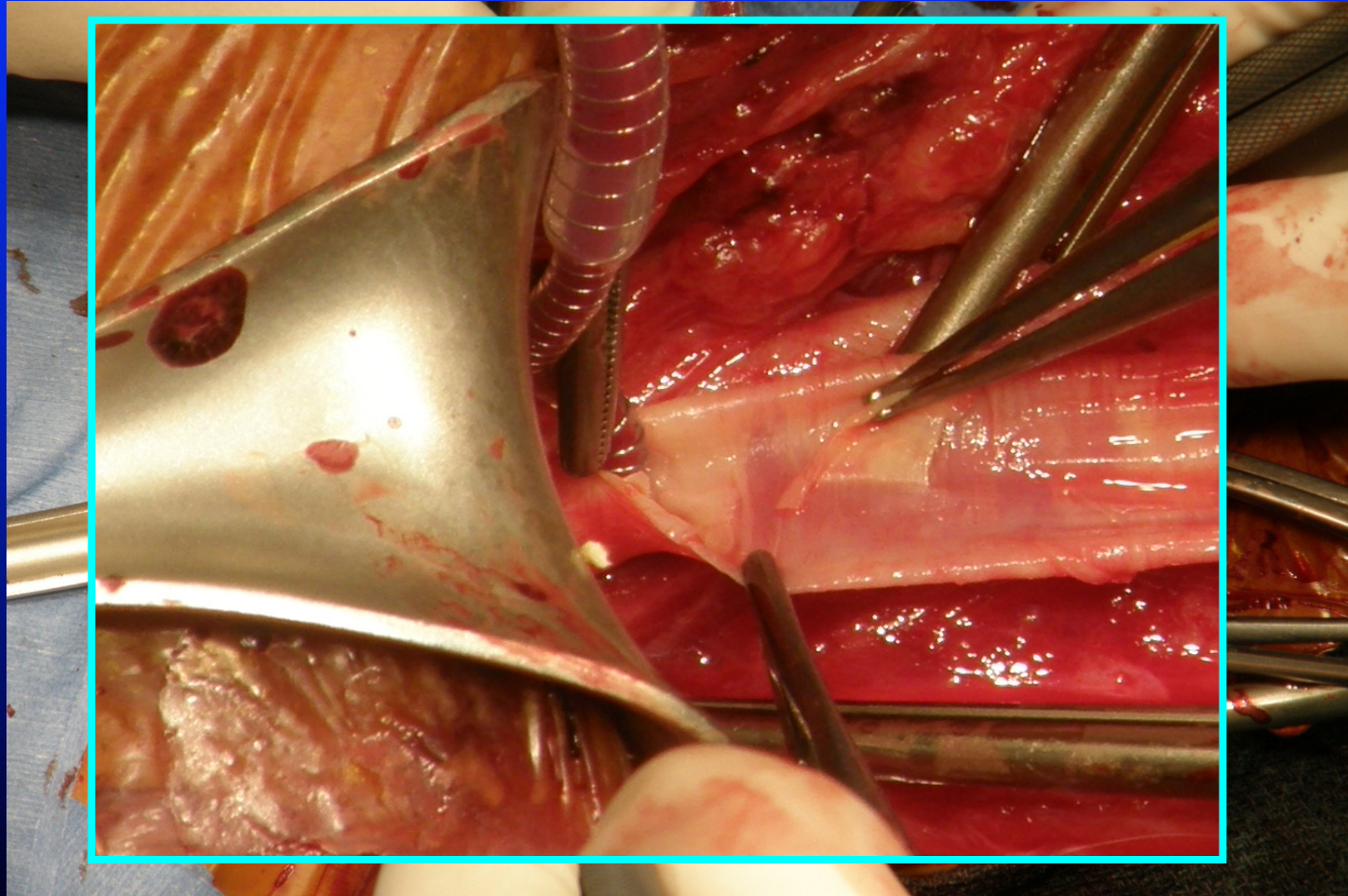
# La Chirurgie: Le Patch



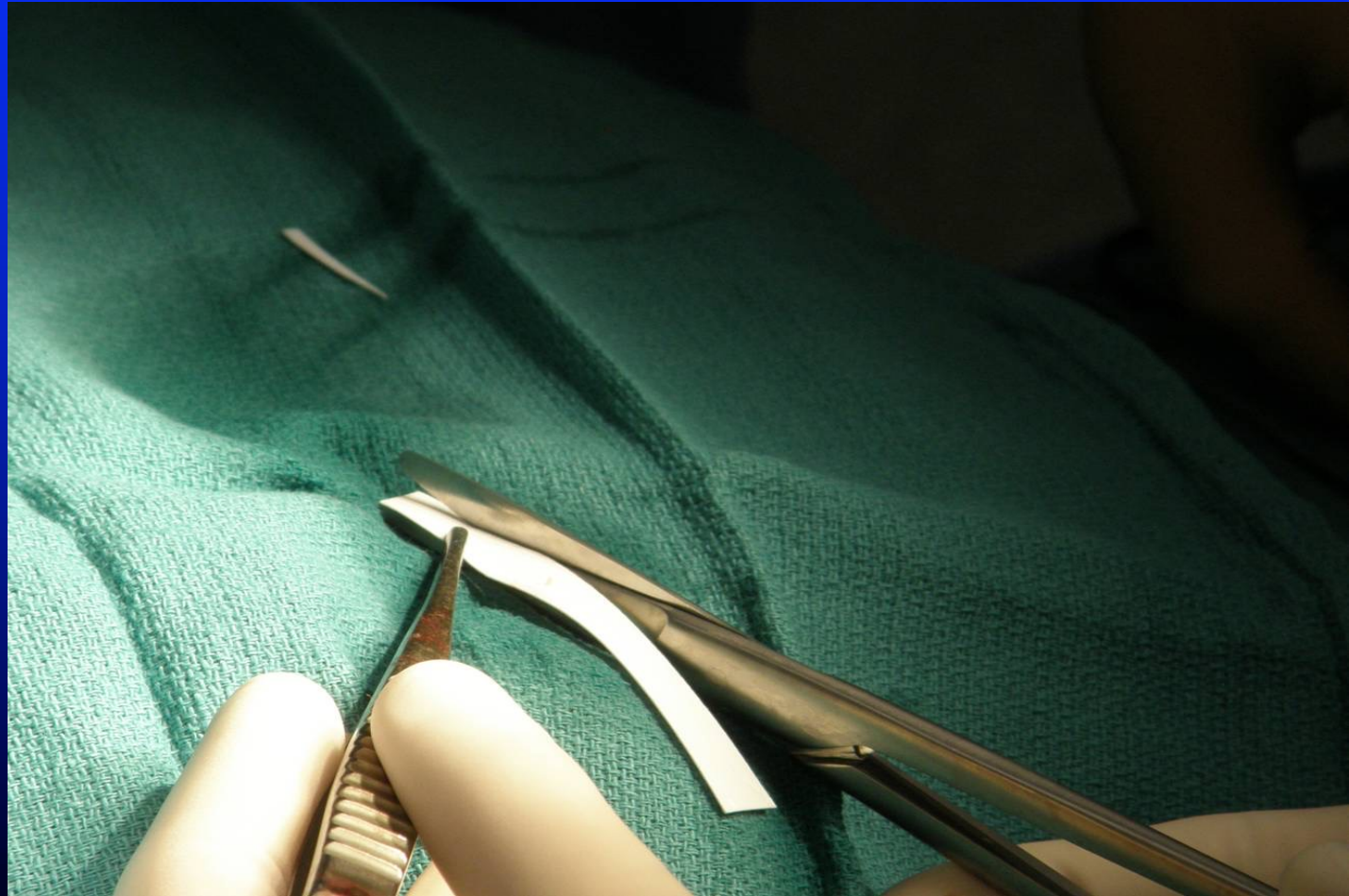
# La Chirurgie: Le Patch



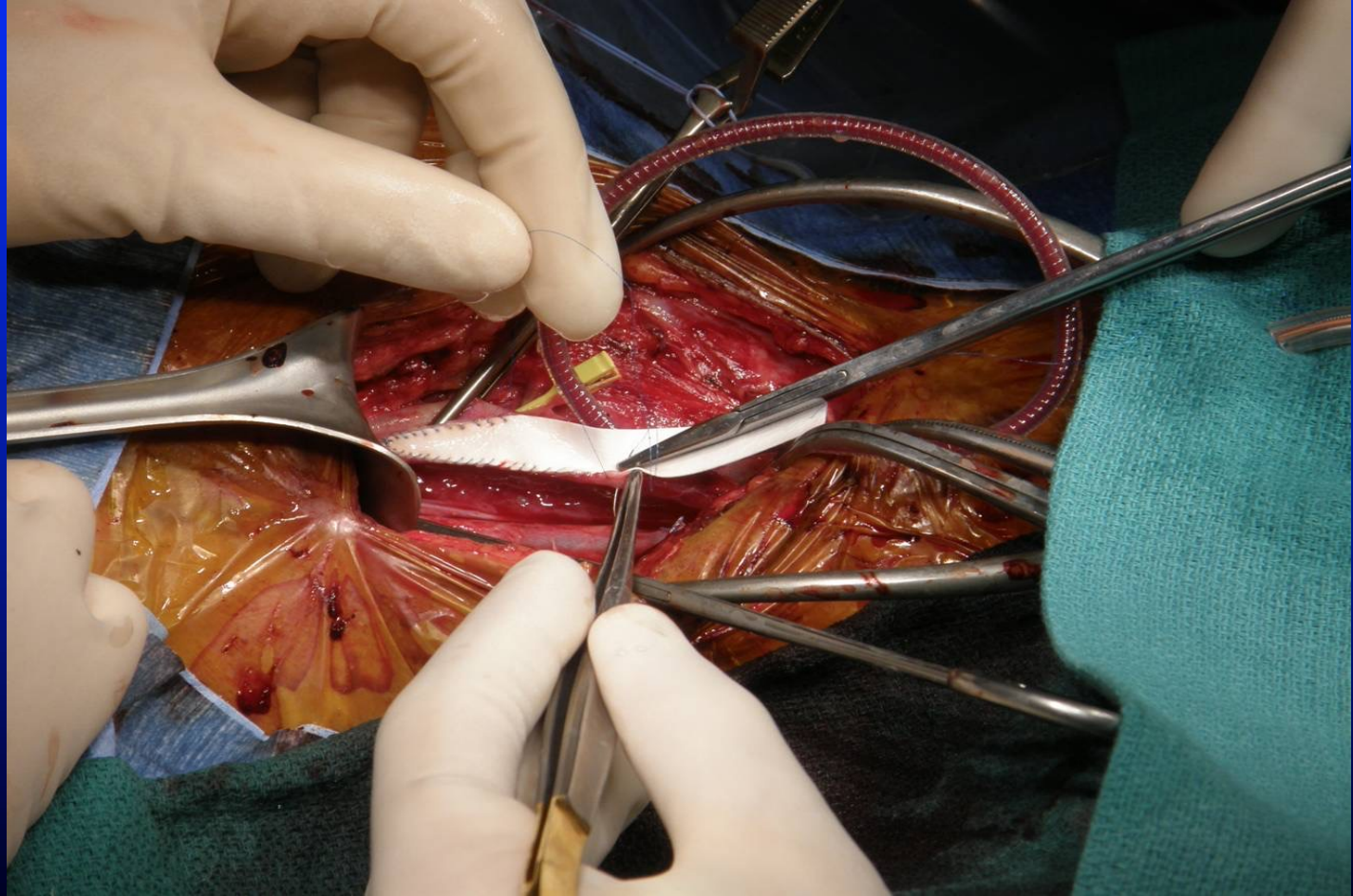
# La Chirurgie: Le Patch



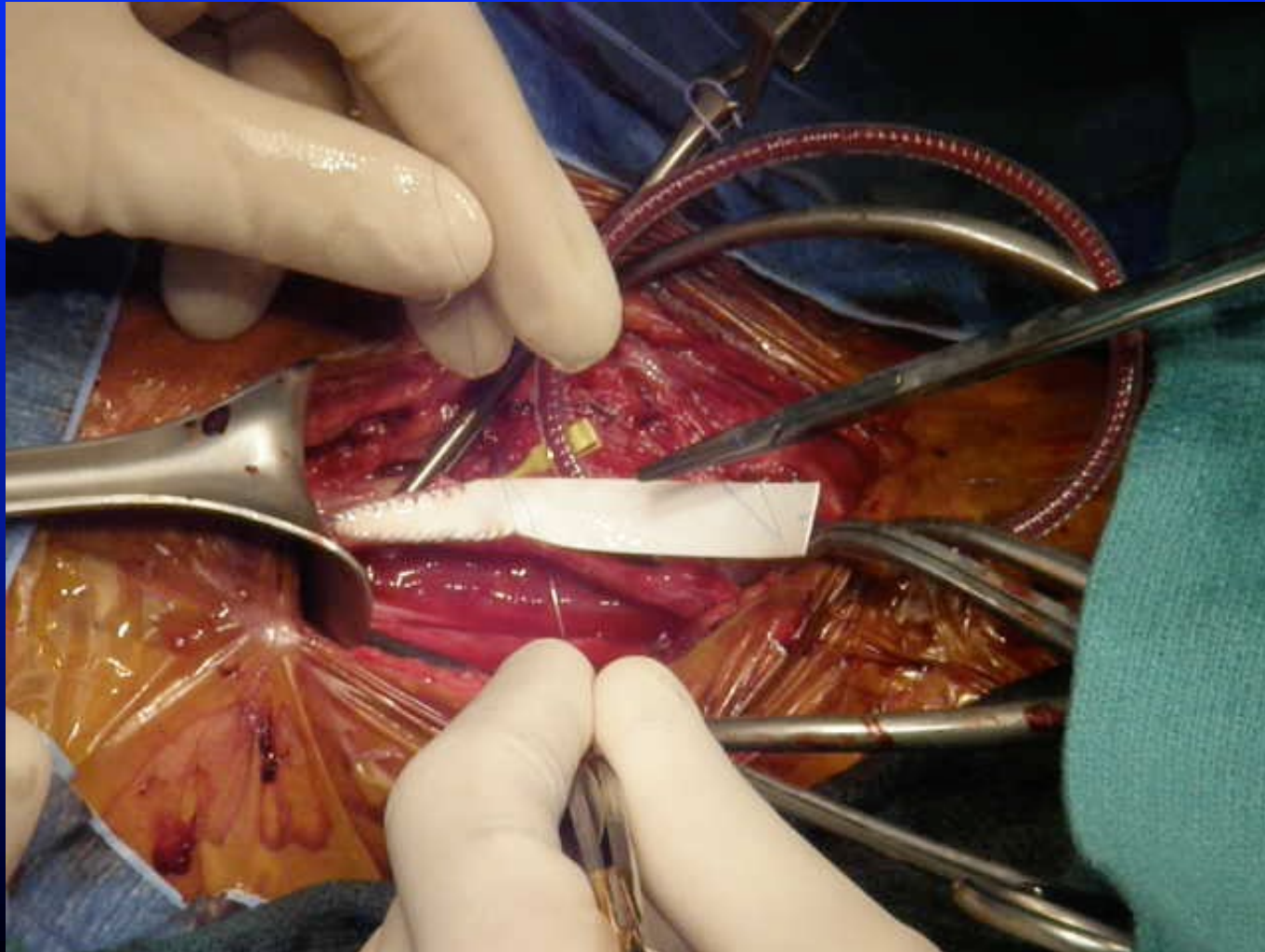
# La Chirurgie: Le Patch



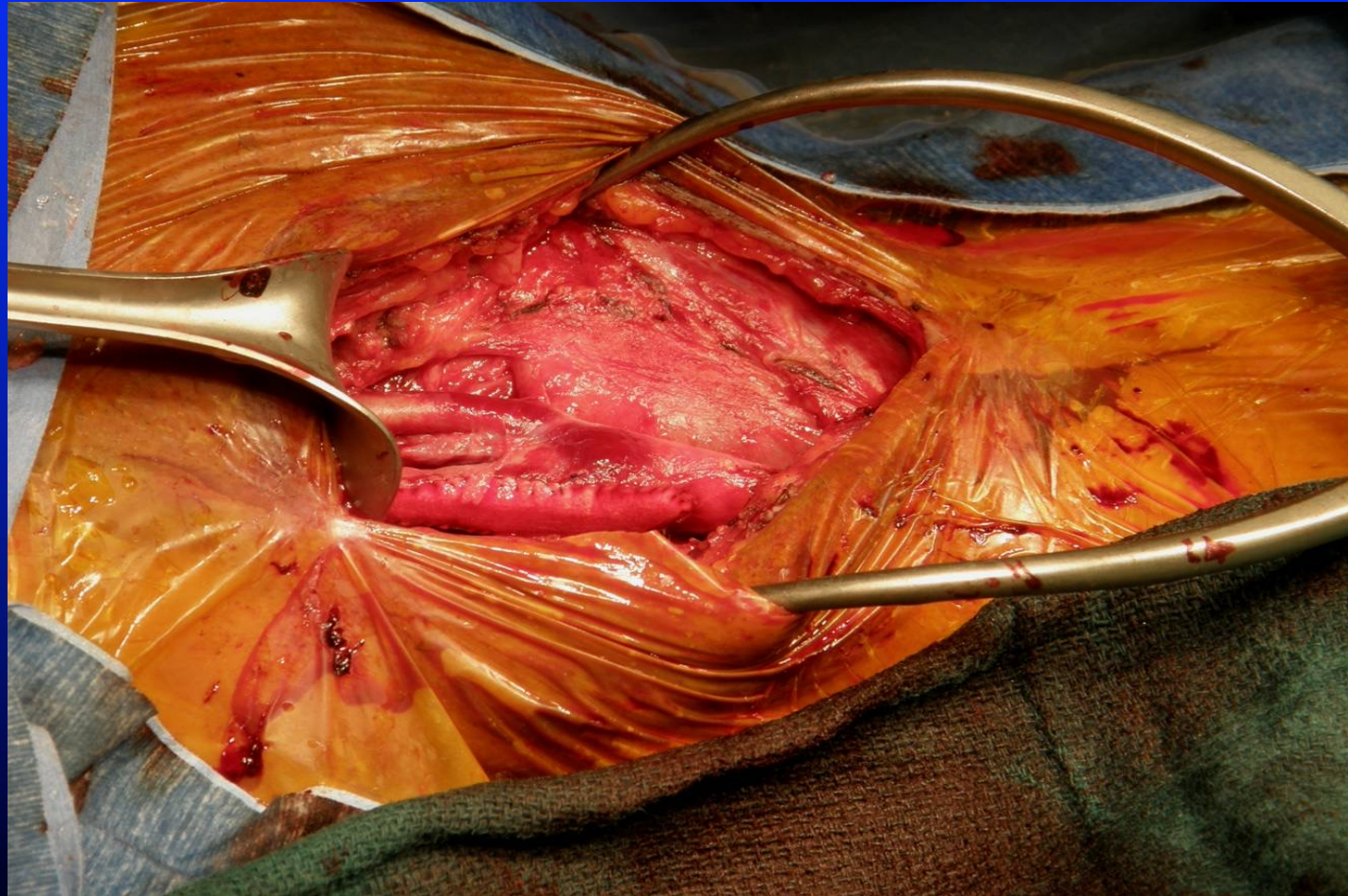
# La Chirurgie: Le Patch



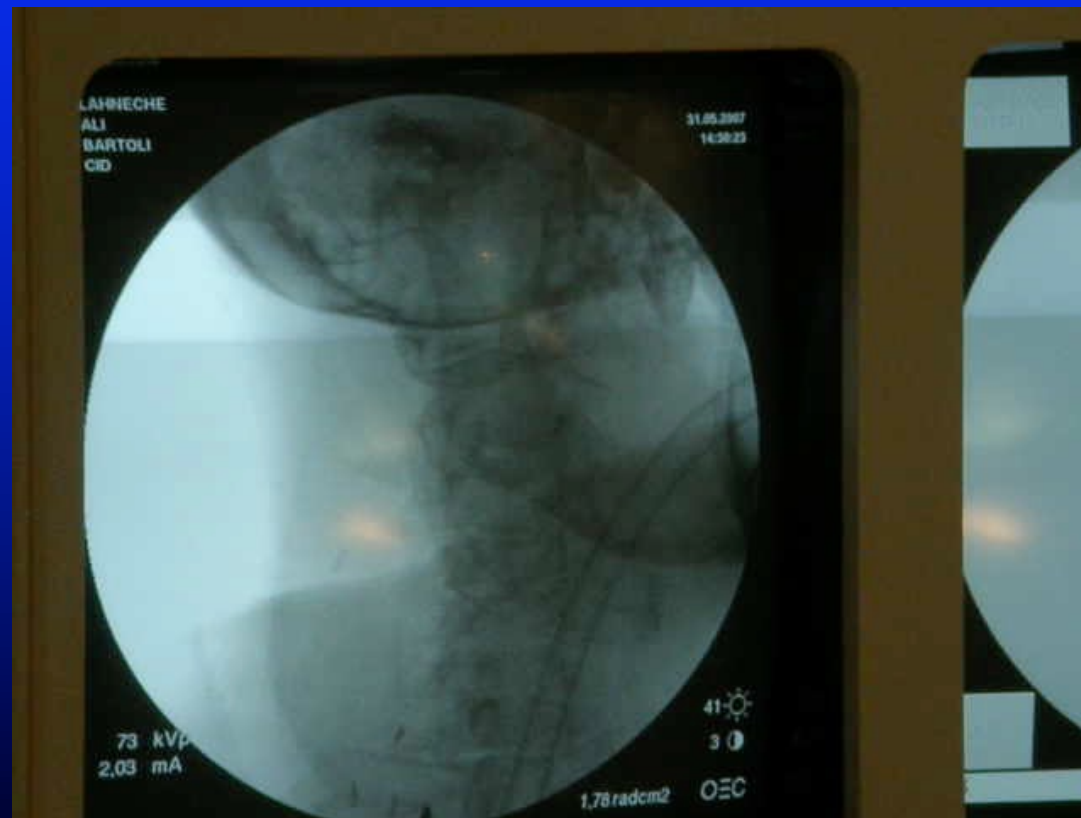# La Chirurgie: Le Patch



# La Chirurgie: Le Patch

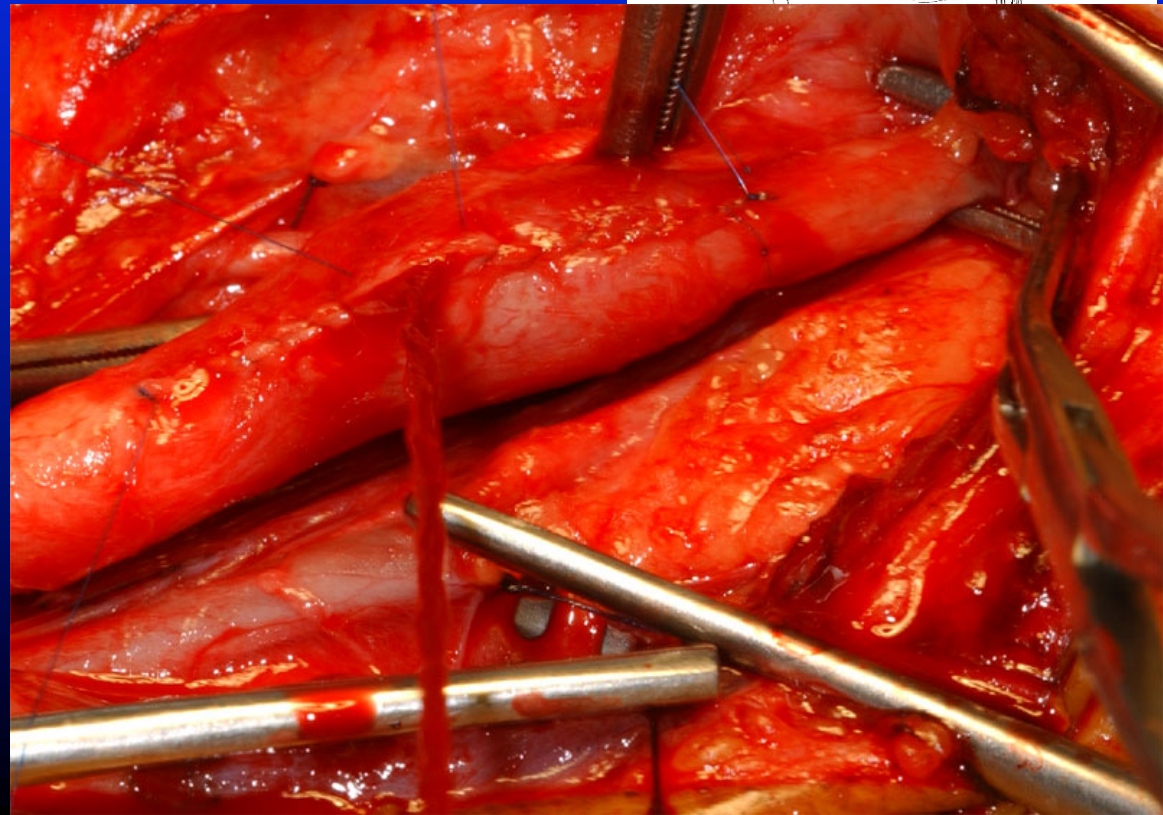
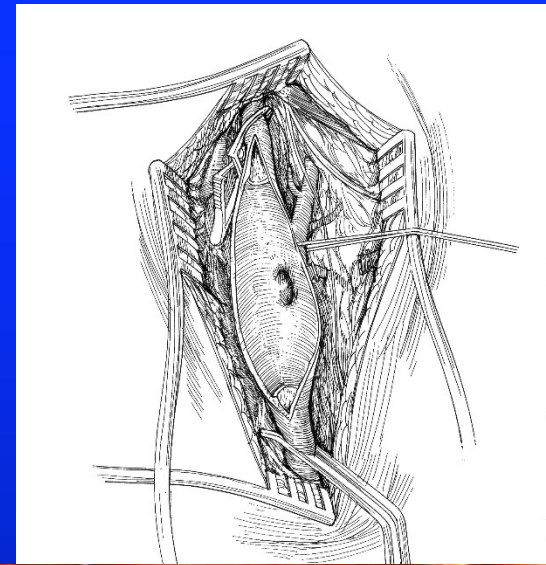
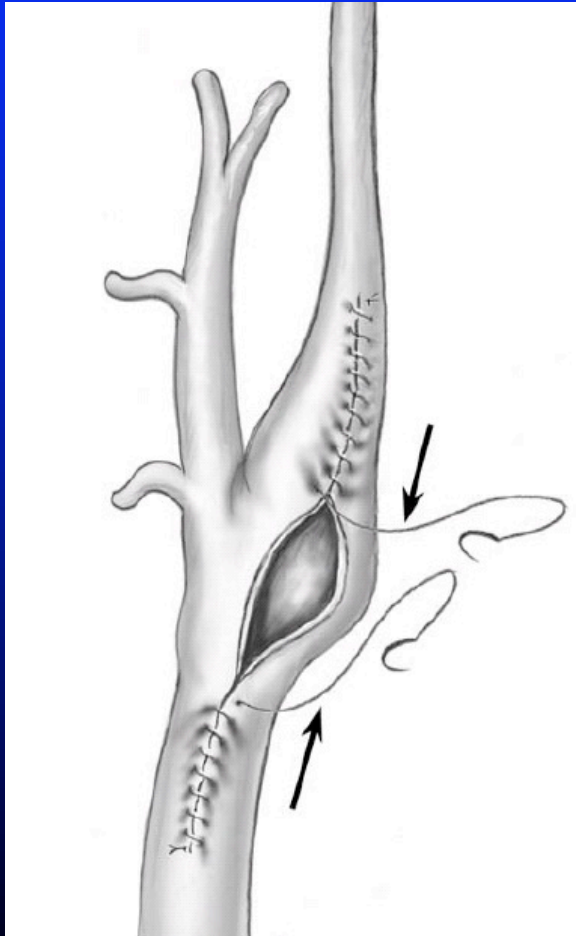


# Chirurgie: Contrôle Per opératoire Patch

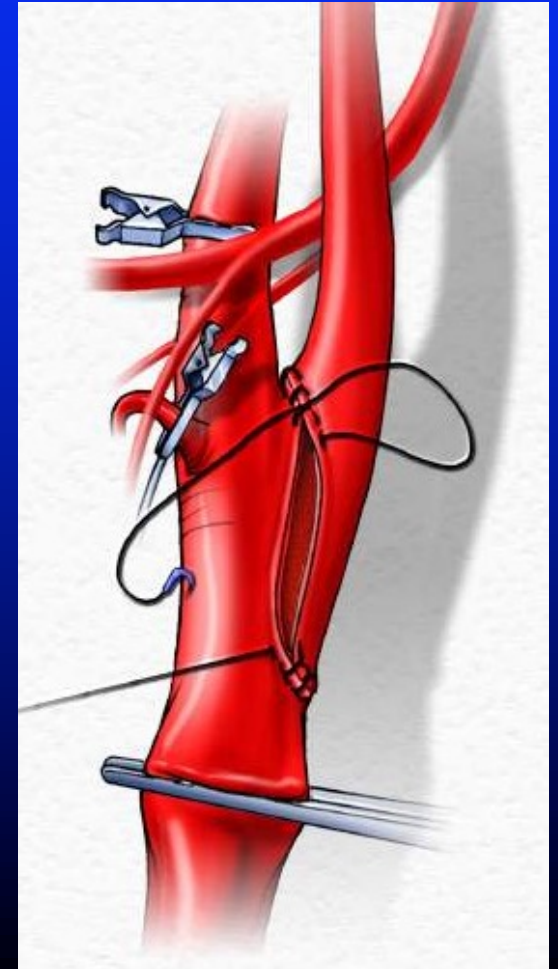
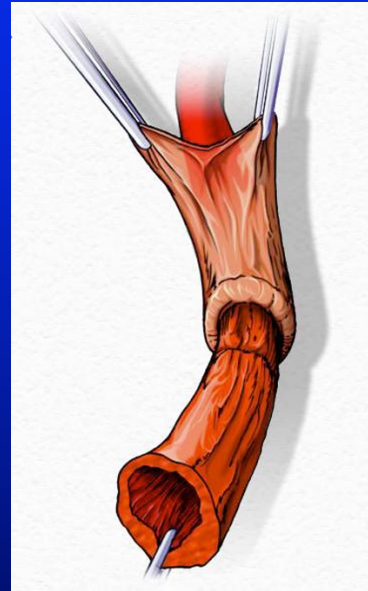
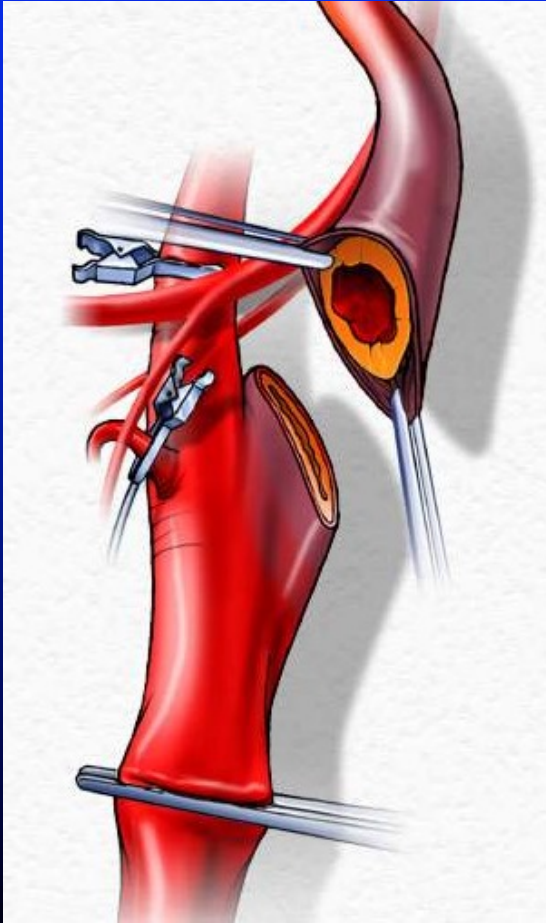




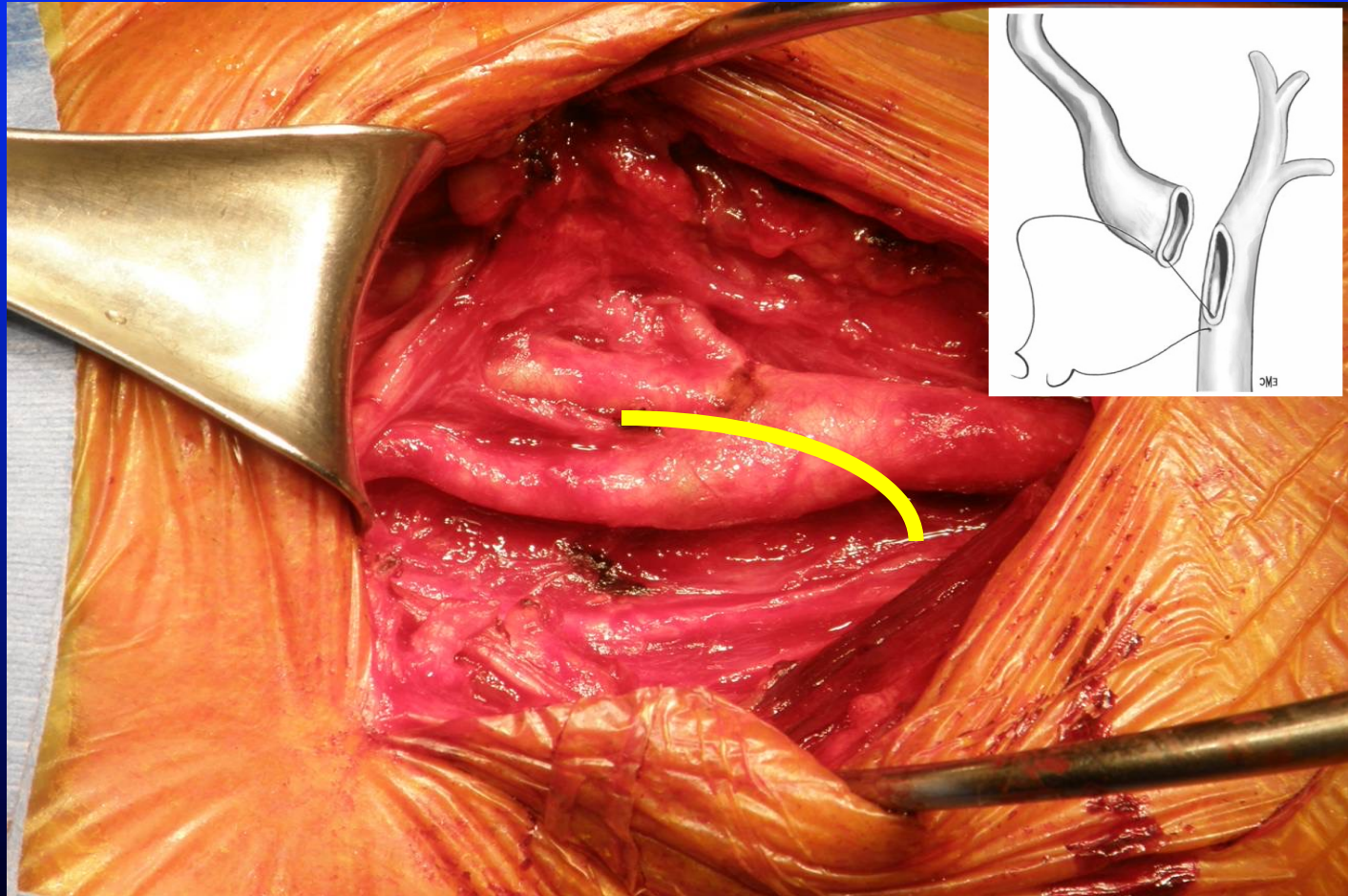
# Suture directe



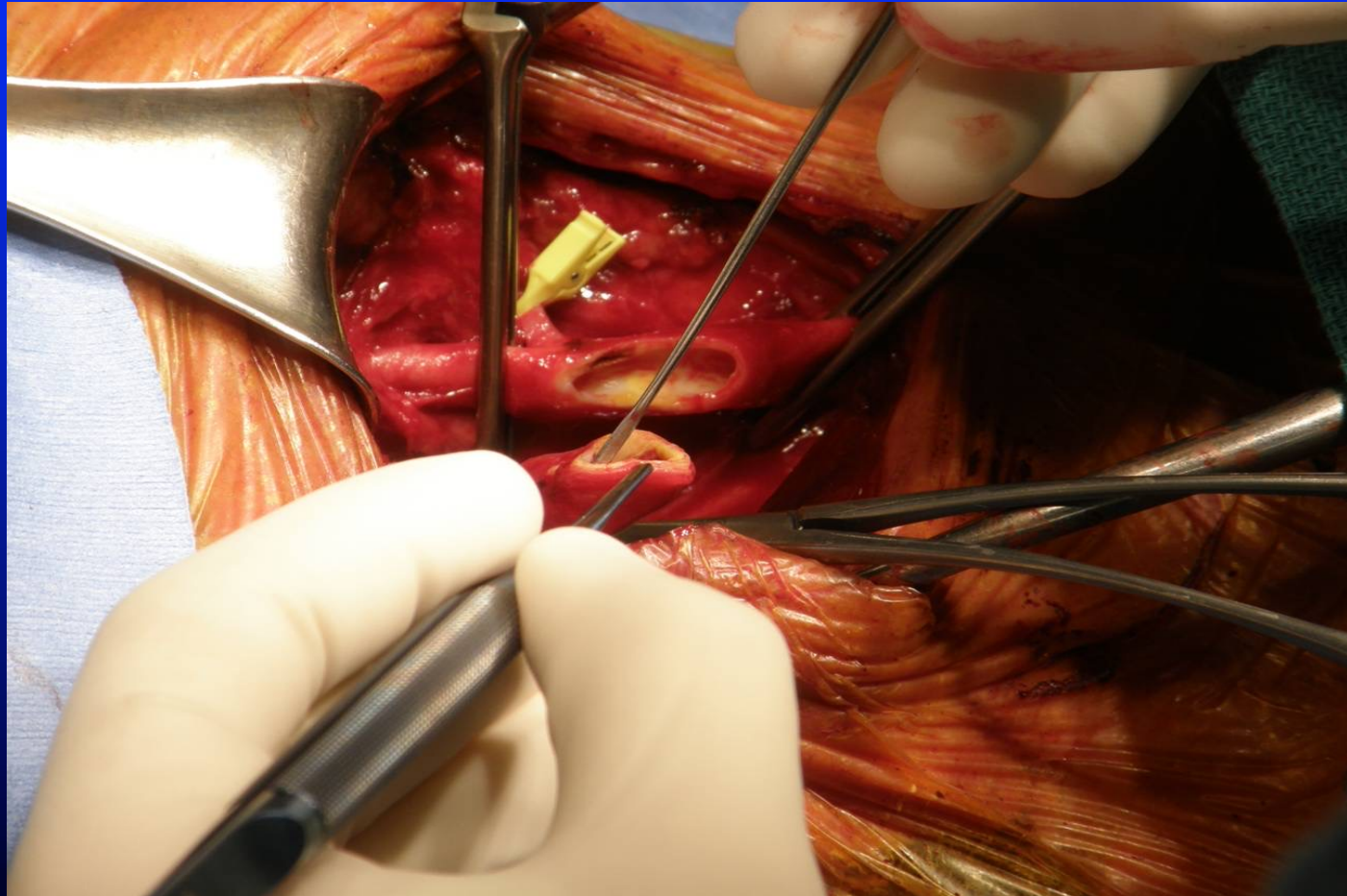
# Endartériectomie par eversion



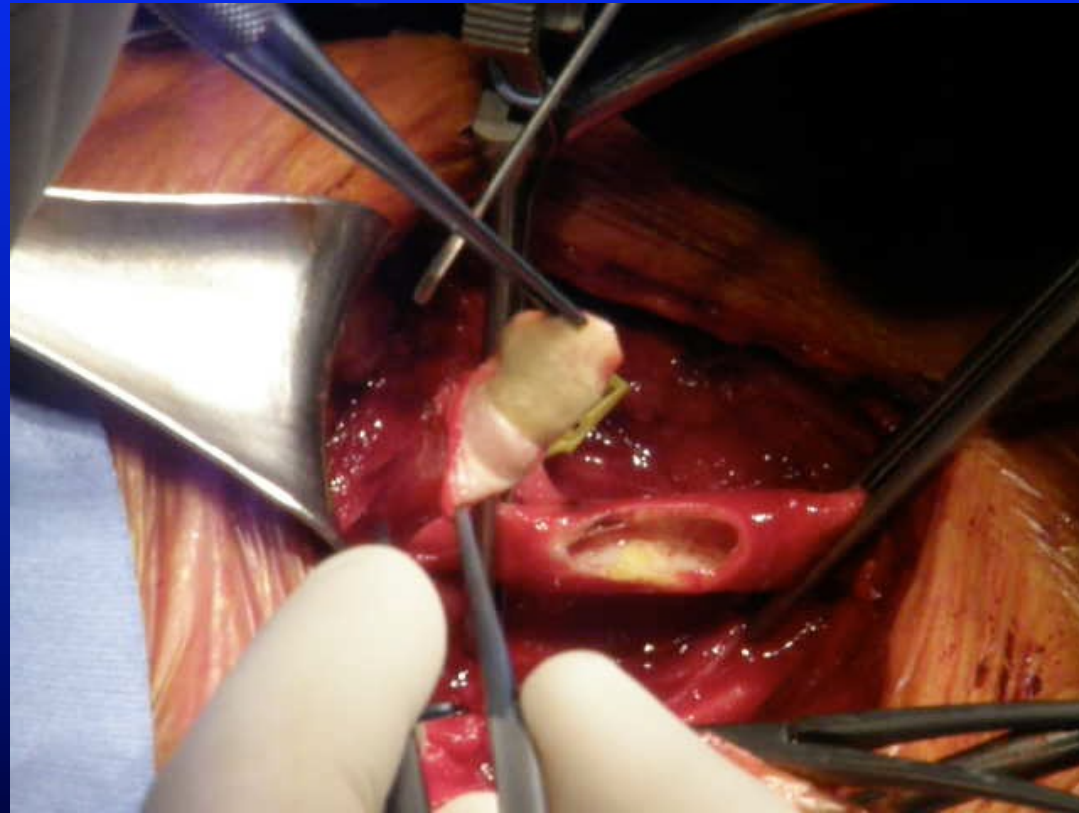
# La Chirurgie: L'Éversion



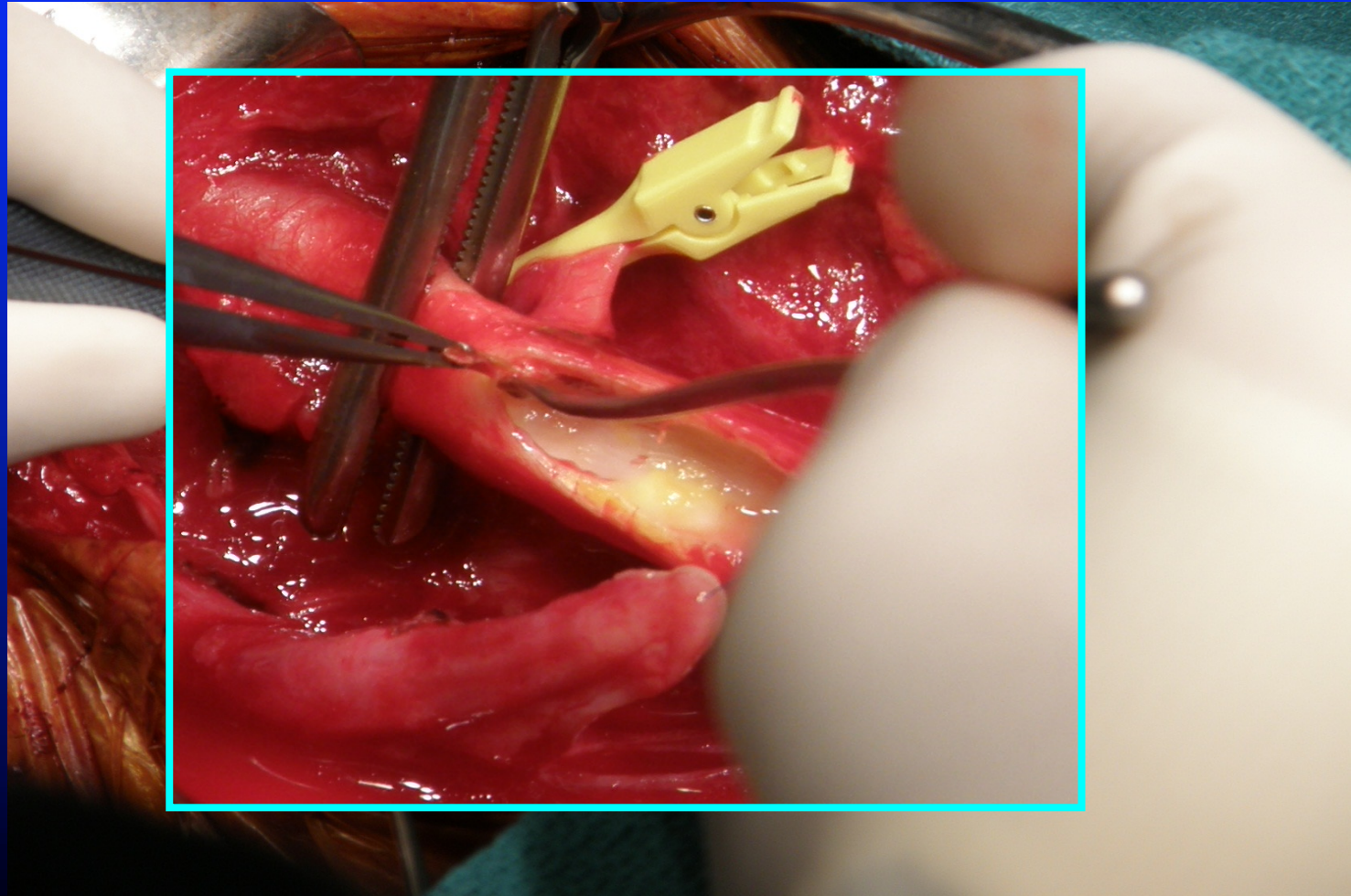
# La Chirurgie: L'Éversion



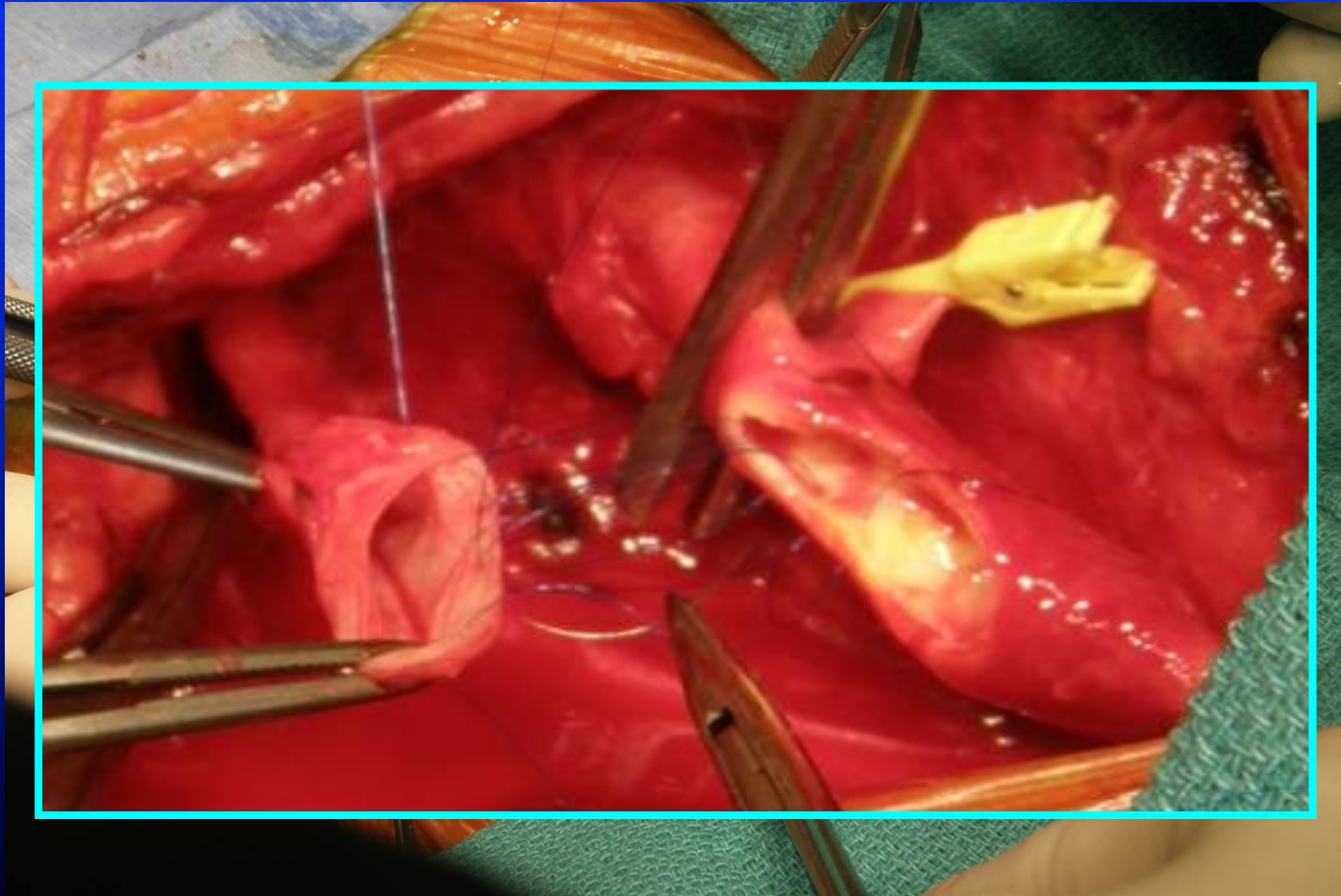
# La Chirurgie: L'Éversion



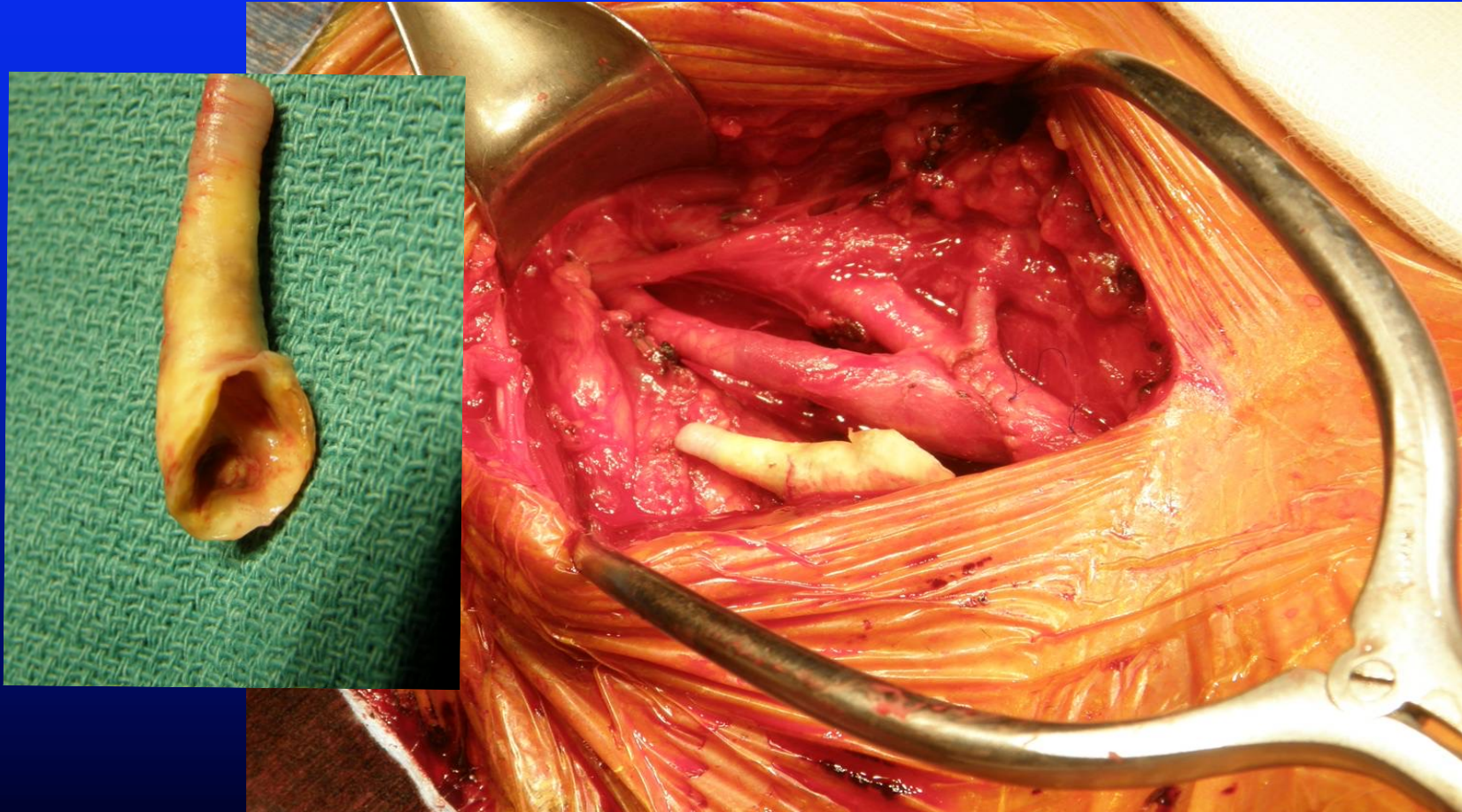
# La Chirurgie: L'Éversion



# La Chirurgie: L'Éversion

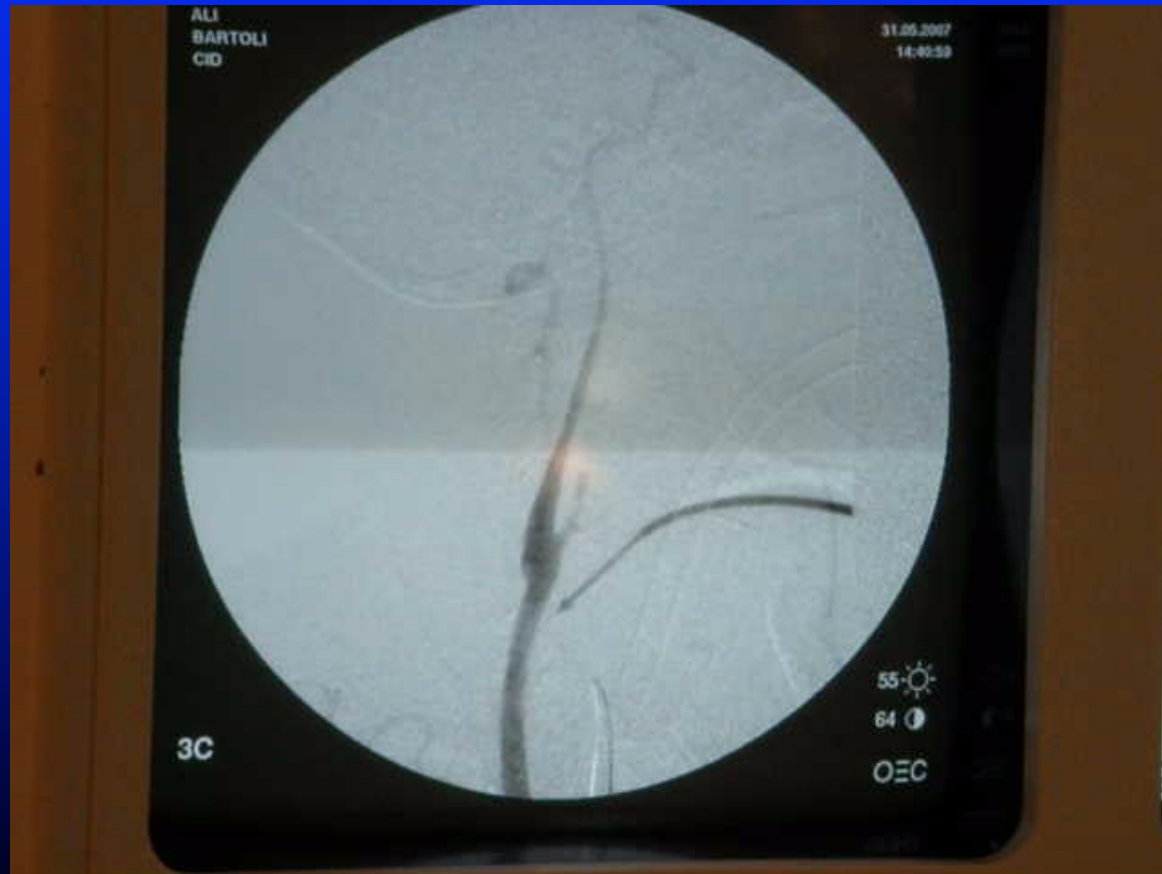

# La Chirurgie: L'Éversion

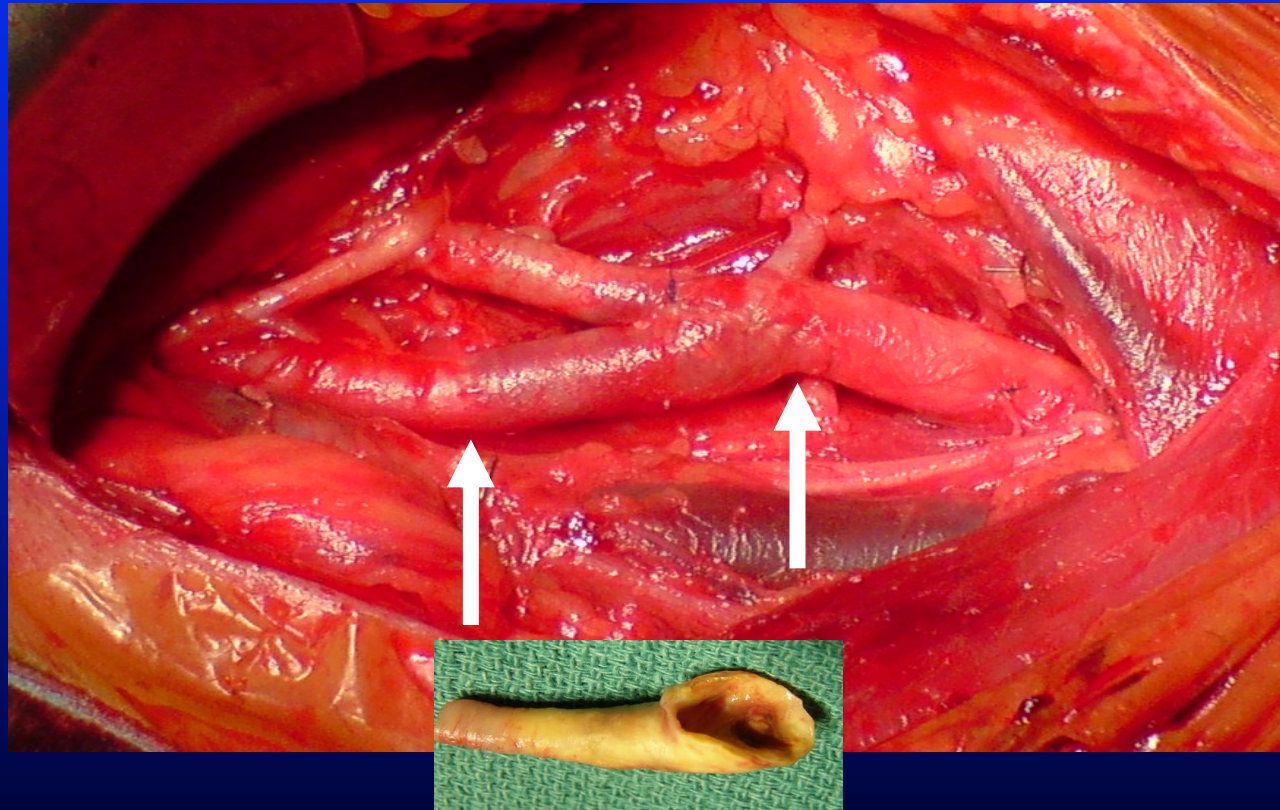




# La Chirurgie: contrôle Eversion



# La Chirurgie: L'Éversion



# EVOLUTION DES TECHNIQUES

## *Eversion vs endarterectomie*

### *Résultats*

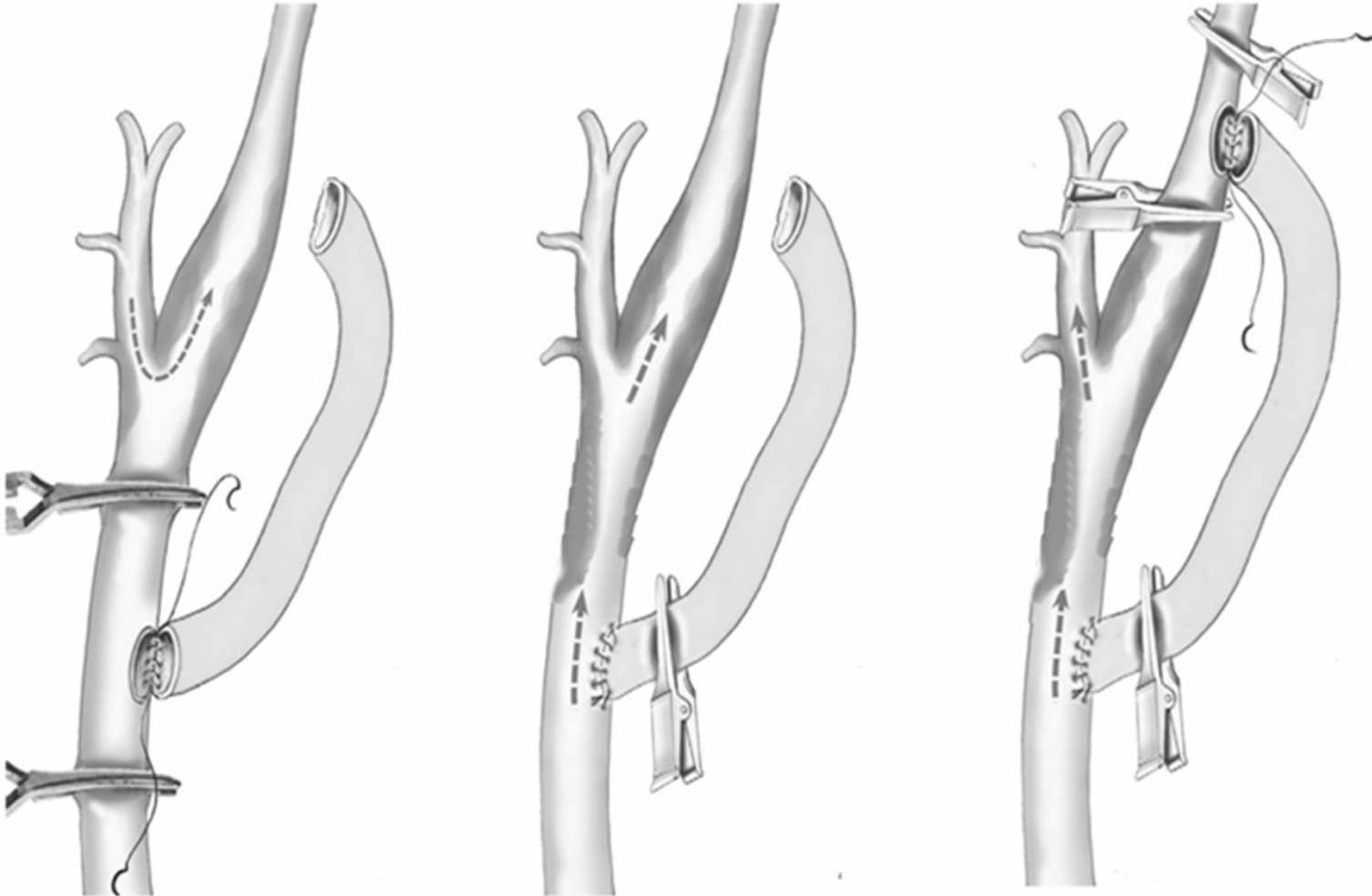
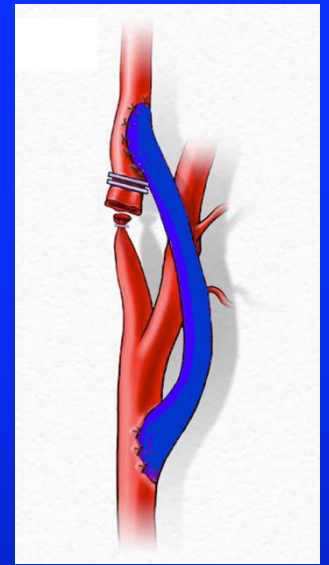
		N	TCMM	Re sténose ou occlusion
<b>Ballotta</b> 1999	Eversion	169	0	0
	Patch	167	2,3%	4,9%
<b>Green</b> 2000	Eversion	107	0,9%	4,6%
	Patch	167	3%	4,7%
<b>Everest Trial</b> 2000	Eversion	678	2,2%	3,6%
	Patch ou Suture simple	675	1,6%	9,2%

# EVOLUTION DES TECHNIQUES

## *Patch versus Suture directe*

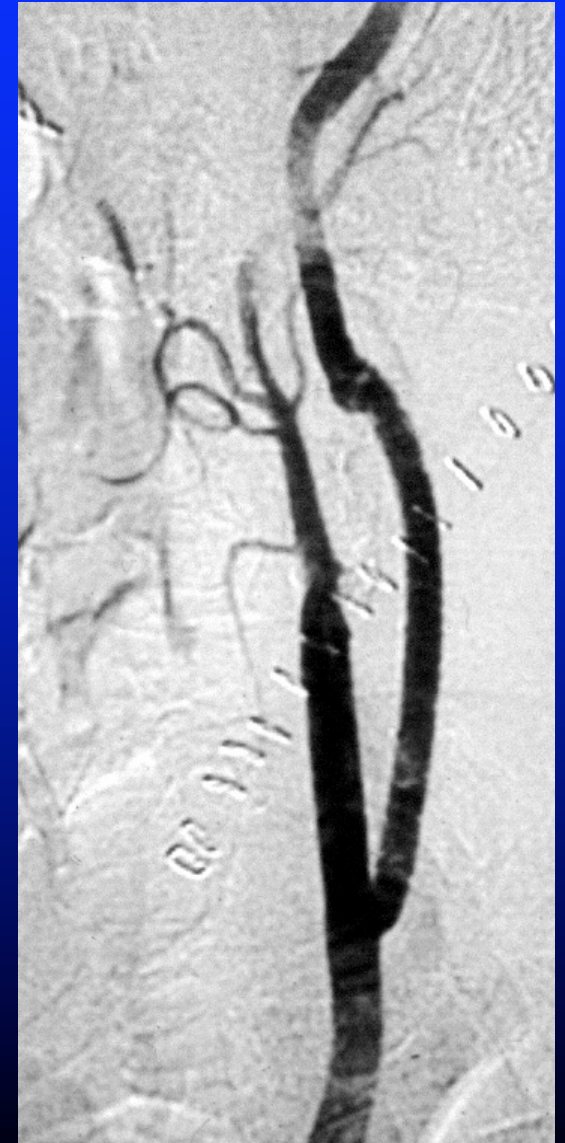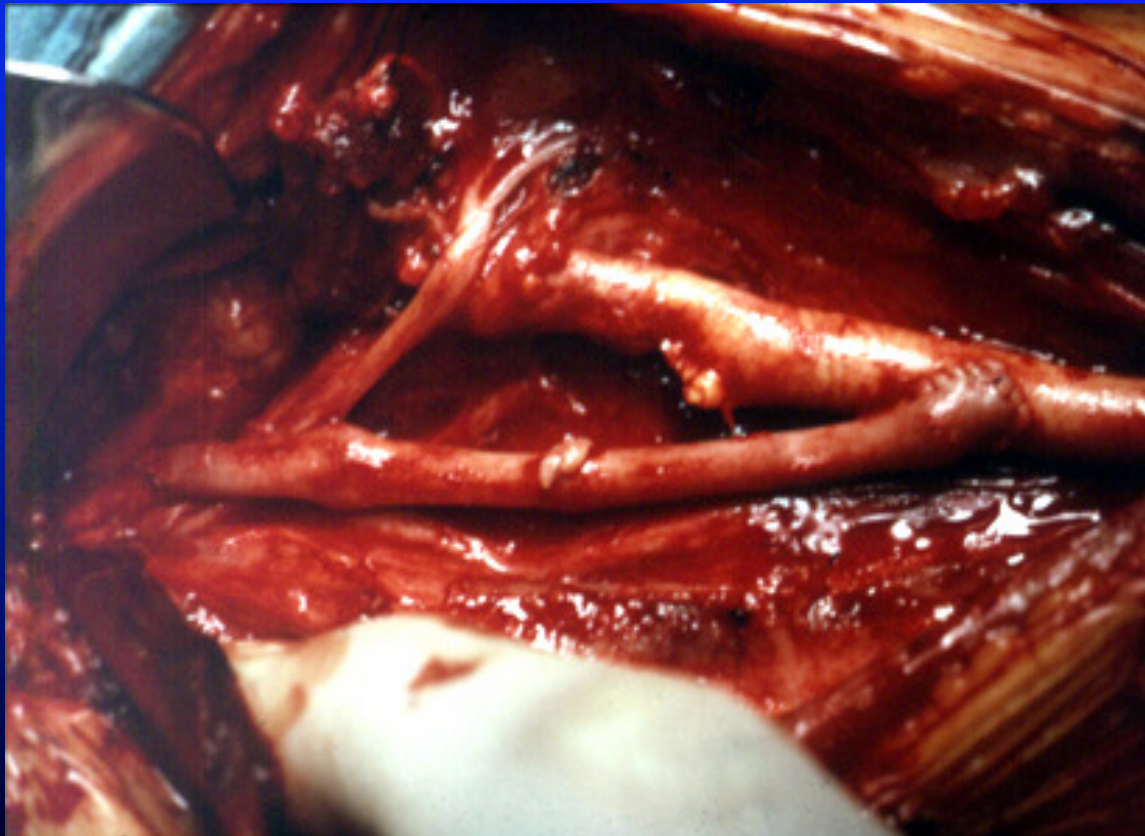
		N	TCMM	Occlusion	Resténose
<b>AbuRahma</b> 1996	Patch	264	3,9%	1,6%	np
	Suture directe	135	5,9%	3,9%	np
<b>Mannheim</b> 2005	Patch	206	3,9%	0,3%	2,2%
	Suture directe	216	2,9%	3,9%	8,6%

# *Pontage carotidien*



*Lésions  
étendues*

# *Pontage carotidien*



# PONTAGE CAROTIDIEN

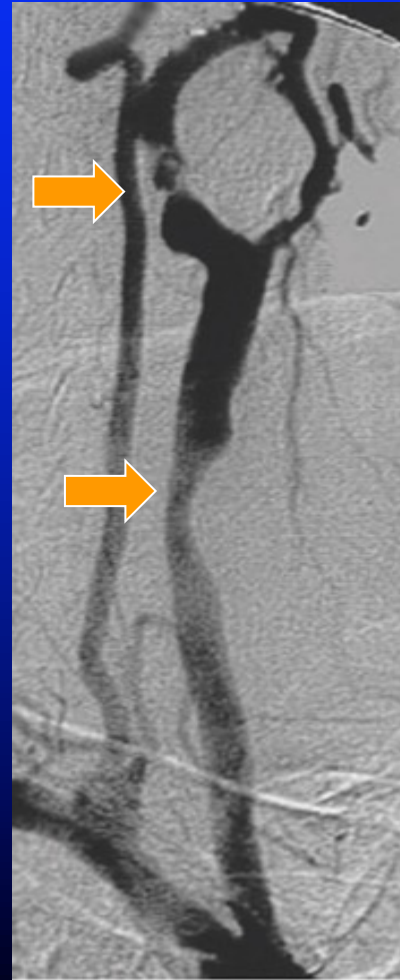
## Indications spécifiques

- Anévrysmes
- Lésions post radiques
- Resténoses
- Traumatismes

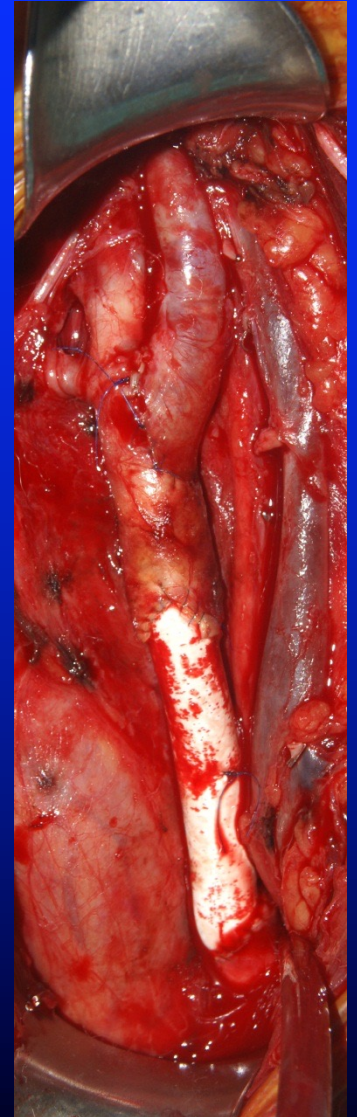
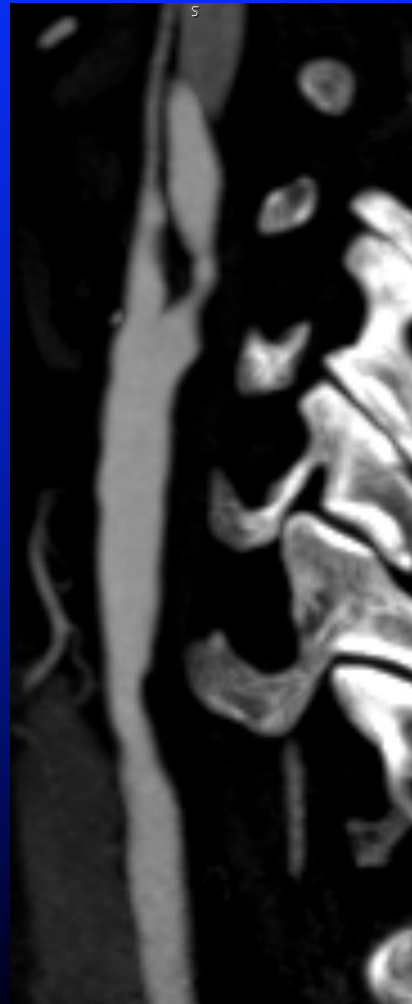
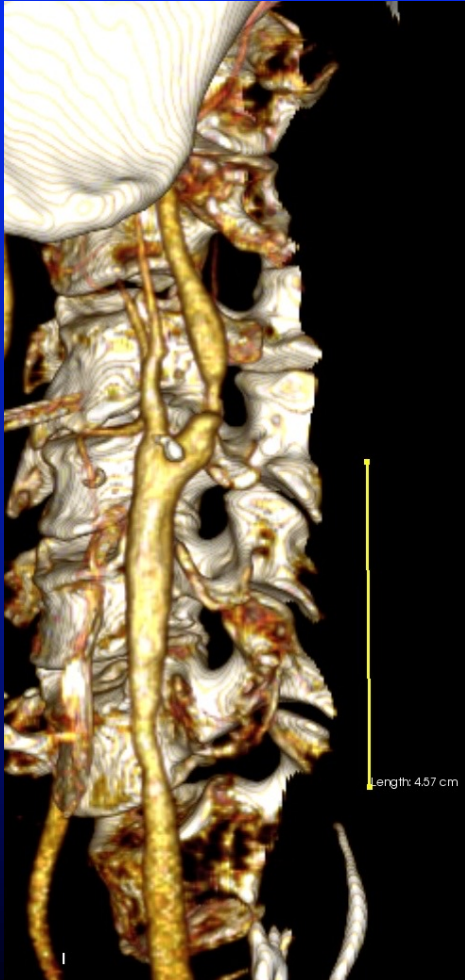## Sténoses athéroscléreuses

- Echet d'endartérectomie
- Sténoses associées à un excès de longueur
- Lésions diffuses de l'axe carotidien CC +/- CI

Veine ou PTFE



# Pontage Carotidien





# Répartition des mécanismes de complications neurologiques

```
graph TD; A[Répartition des mécanismes de complications neurologiques] --> B[Thromboembolique 40-70%]; A --> C[Intolérance Clampage 10-30%]; A --> D[Reperfusion 10-30%];
```

**Thrombo  
embolique  
40-70%**

**Intolérance  
Clampage  
10-30%**

**Reperfusion  
10-30%**

# PROTECTION CEREBRALE

## *Monitoring*

### *Hémodynamique*

Pression résiduelle

Oxymétrie jugulaire

PO<sub>2</sub> trans-frontale

### *Neuro Physio.*

Conscience

Potentiels évoqués

EEG

## *Shunt*

Systematique

Electif

Jamais

# PROTECTION CEREBRALE

## Cochrane's corner Stroke 2002

**There is still insufficient evidence to support or refute the use of  
routine or selective shunting ...**

**There is little evidence to support the use of one form of  
monitoring over another ....**

# Routine or selective carotid artery shunting for carotid endarterectomy (and different methods of monitoring in selective shunting) (Review)

Rerkasem K, Rothwell PM

This is a reprint of a Cochrane review, prepared and maintained by The Cochrane Collaboration and published in *The Cochrane Library* 2009, Issue 4

<http://www.thecochranelibrary.com>

Cochrane Database of Systematic Reviews

## Routine or selective carotid artery shunting for carotid endarterectomy (and different methods of monitoring in selective shunting)

Cochrane Systematic Review - Intervention | Version published: 23 June 2014 [see what's new](#)

### Authors' conclusions

This review concluded that the data available were too limited to either support or refute the use of routine or selective shunting in carotid endarterectomy. It was suggested that large scale randomised trials between routine shunting versus selective shunting were required. No one method of monitoring in selective shunting has been shown to produce better outcomes.

# PROTECTION CEREBRALE

## *Notre opinion*

***Shunt***

Occlusion contro-latérale

Urgence

Etat neurologique instable

Réintervention

***Les nouvelles sténoses  
symptomatiques***

# CONTROLE PER-OPERATOIRE

## *Echodoppler*

- Peu utilisé en France
- Avantage : données hémodynamiques et morphologiques

	N	ANOMALIES	SUIVI (mois)	RESTENOSE Doppler normal Vs Anomalies mineures
<b>Baker</b> 1994	316	19,6%	21,6	4,3% vs 17%
<b>Bandick</b> 1988	250	6%	24	9% vs 21%

# ANGIOGRAPHIE PER-OPERATOIRE

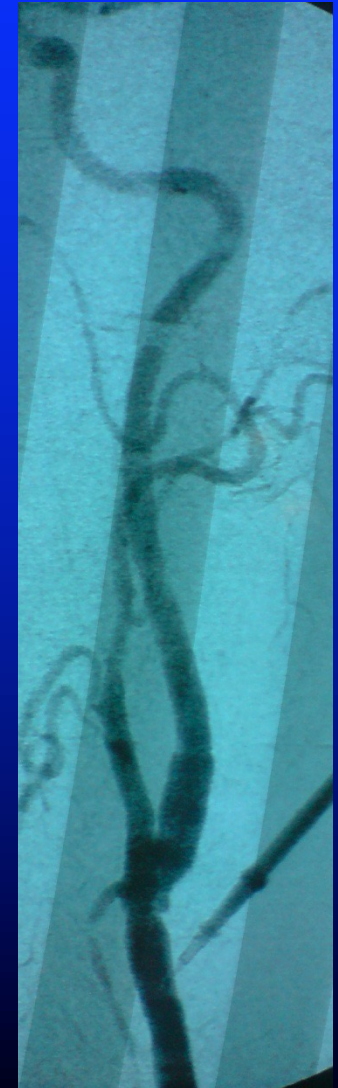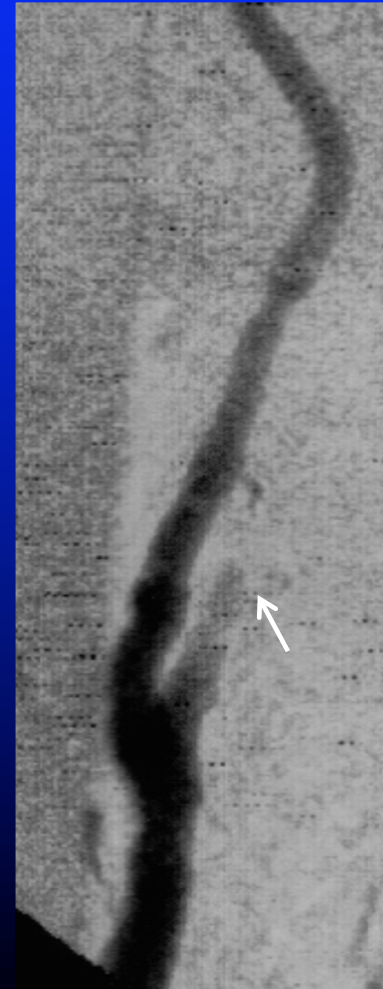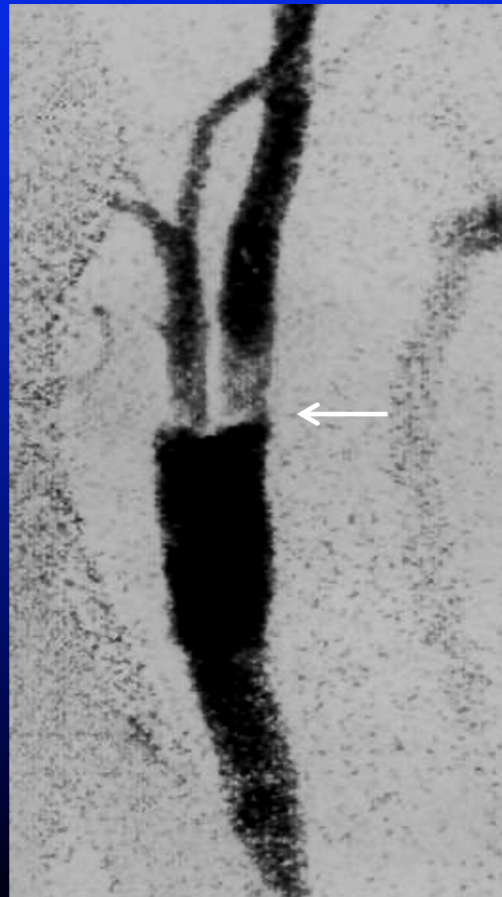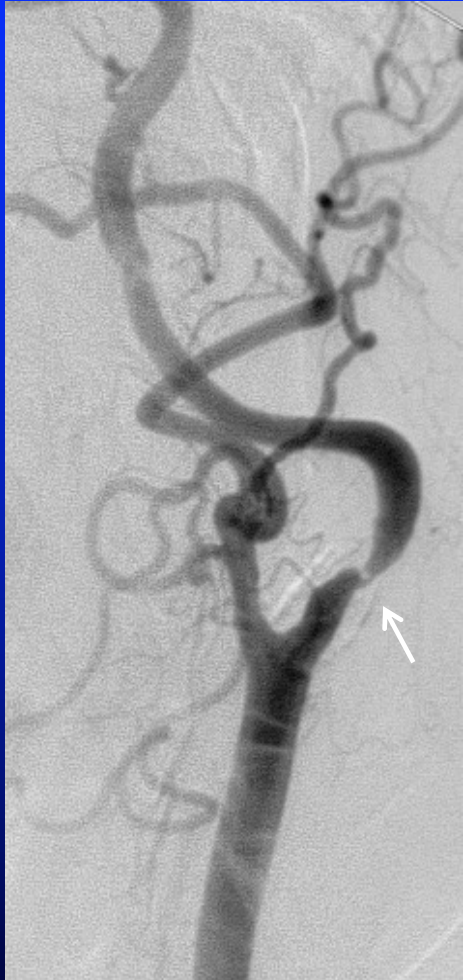Enquête de pratique SCV 2003 : 45%

## Etudes comparatives

	Avec		Sans	
	N	TCMM %	N	TCMM %
<b>Roon</b> 1992	535	1,3%	157	4,5%
<b>Ricco</b> 1996	112	0,9%	114	3,5%

# CONTROLE PER-OPERATOIRE

## *Angiographie per-op*





**Choix de la technique  
la mieux adaptée  
à la lésion**

**Aspirine périop.  
Statines**

# **Quatre Pierres Angulaires**

**Contrôle  
angiographique  
peropératoire**

**Shunt sélectif**



# Angioplastie Carotidienne

Pr Michel Bartoli

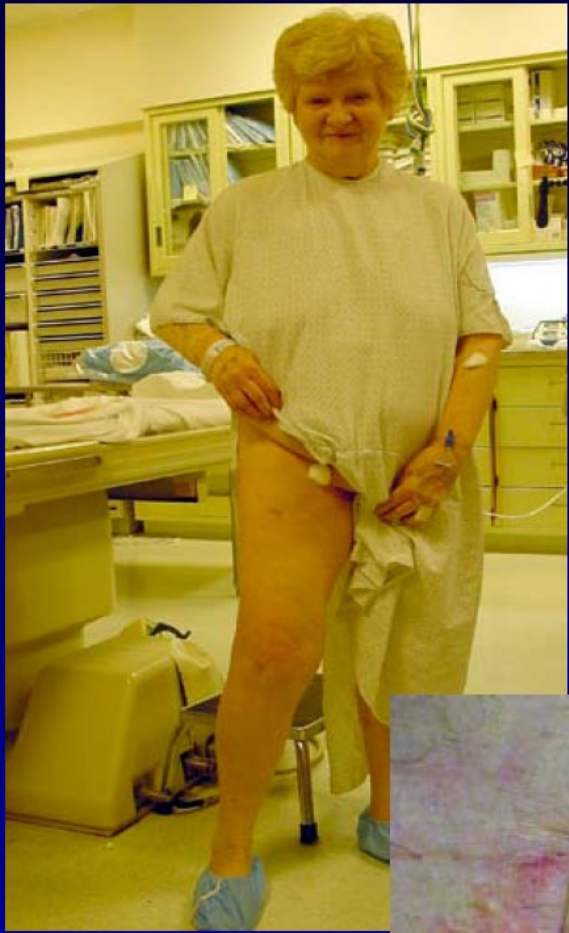# Pourquoi Dilater les Carotides ?

## La chirurgie:

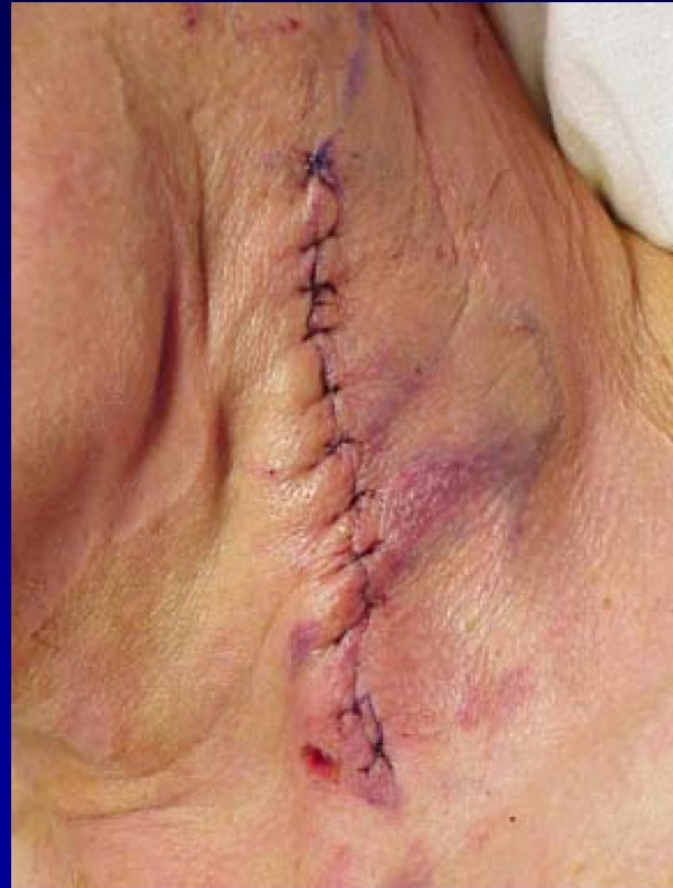- Sure, efficace
- Une durée de séjour limitée
- Un recul très important
- Seule technique opposée au BMT

## Les avantages de l'angioplastie:

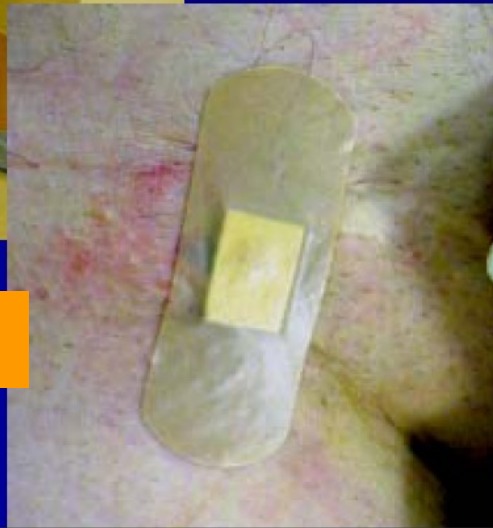- Pas de cicatrice
- Pas de risque de lésion des nerfs crâniens
- Sous anesthésie locale



ou CHIRURGIE ???



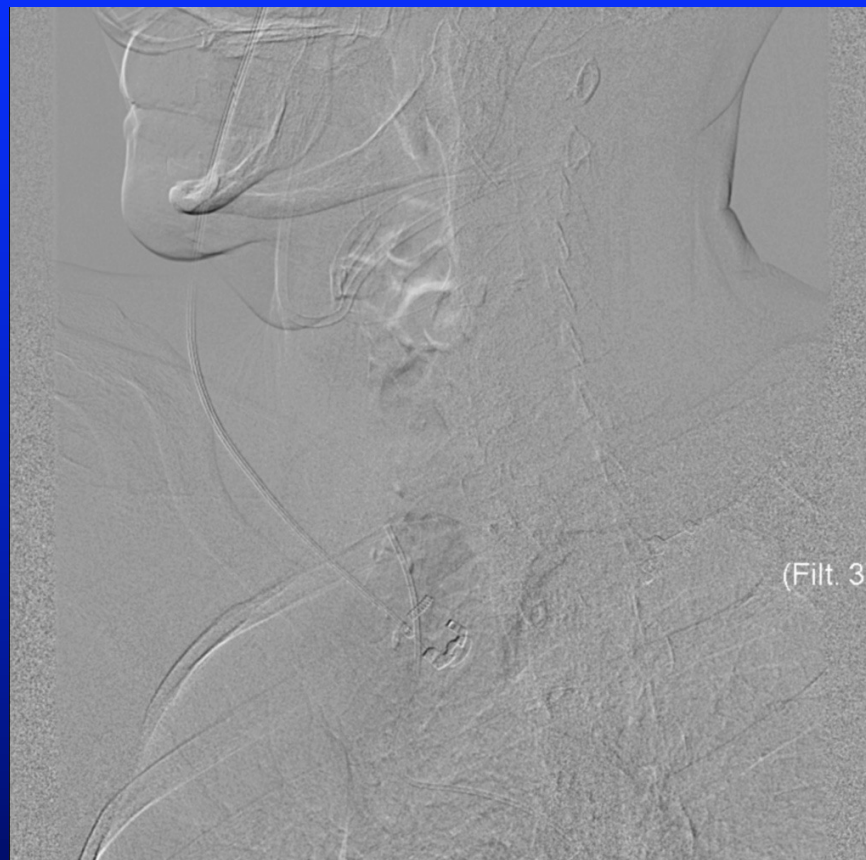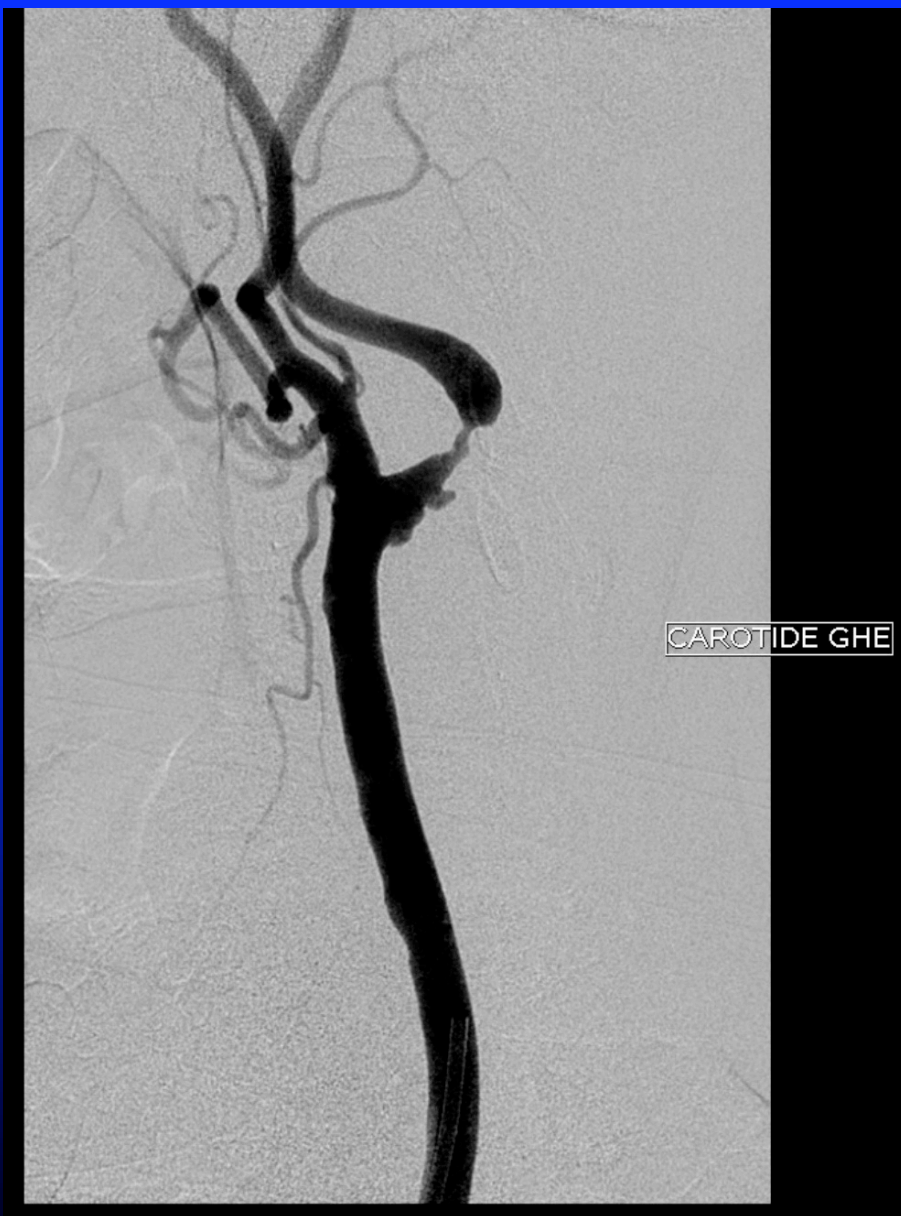STENTING...

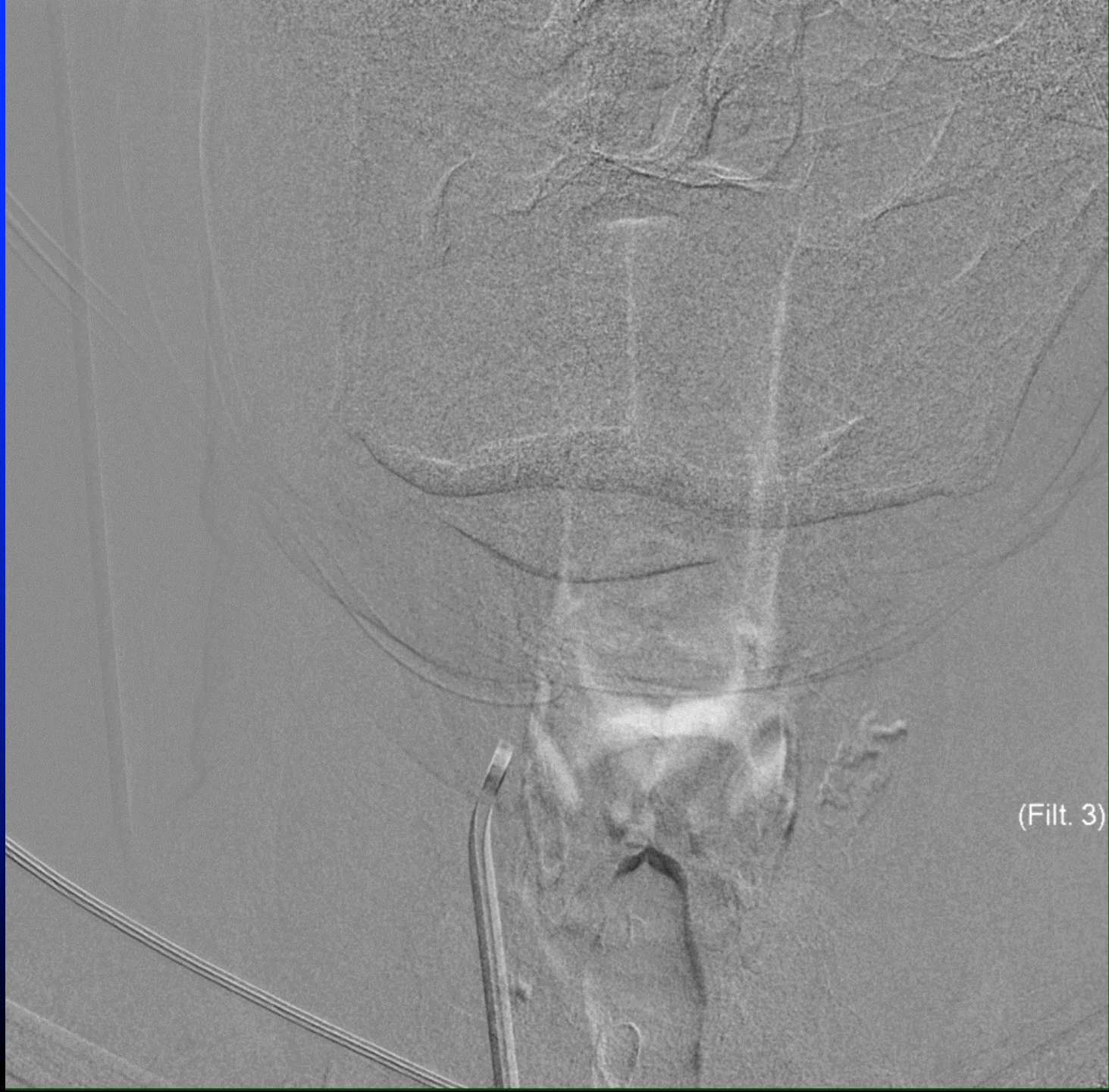

# La Technique

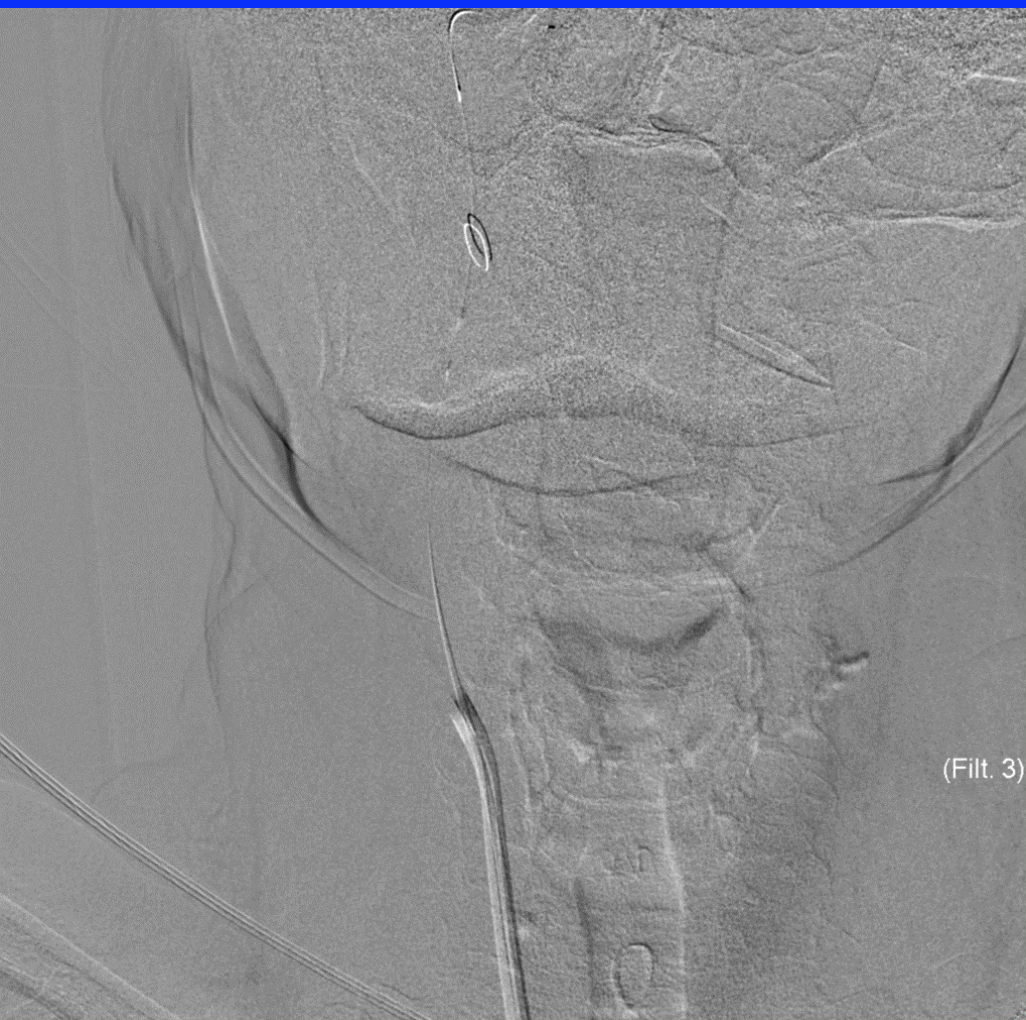Ponction fémorale, exceptionnellement cervicale

GUIDANT



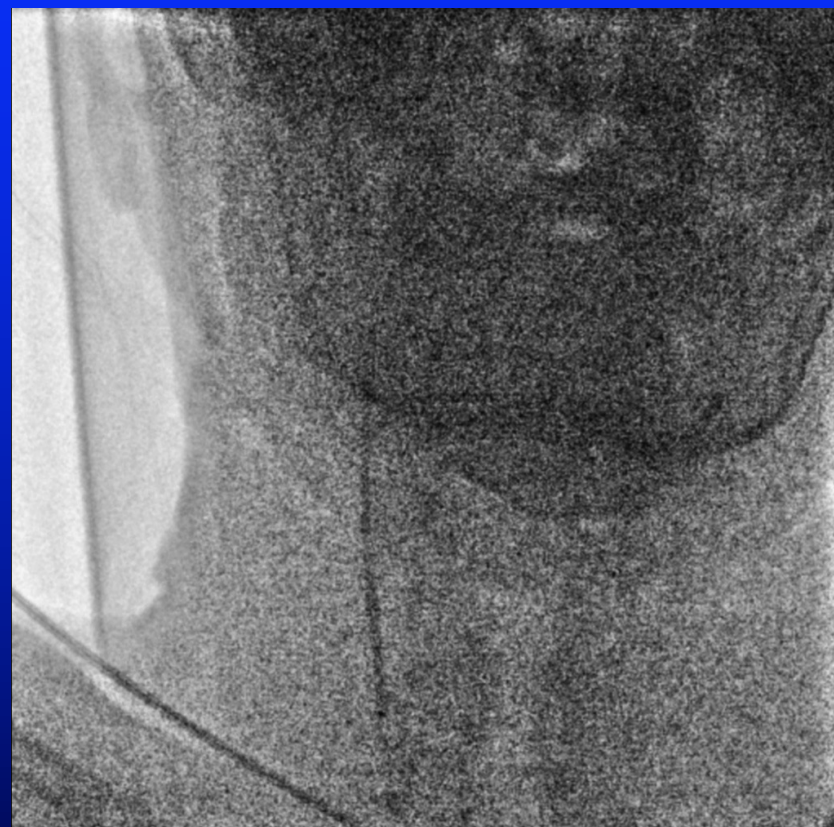

(Filt. 3)



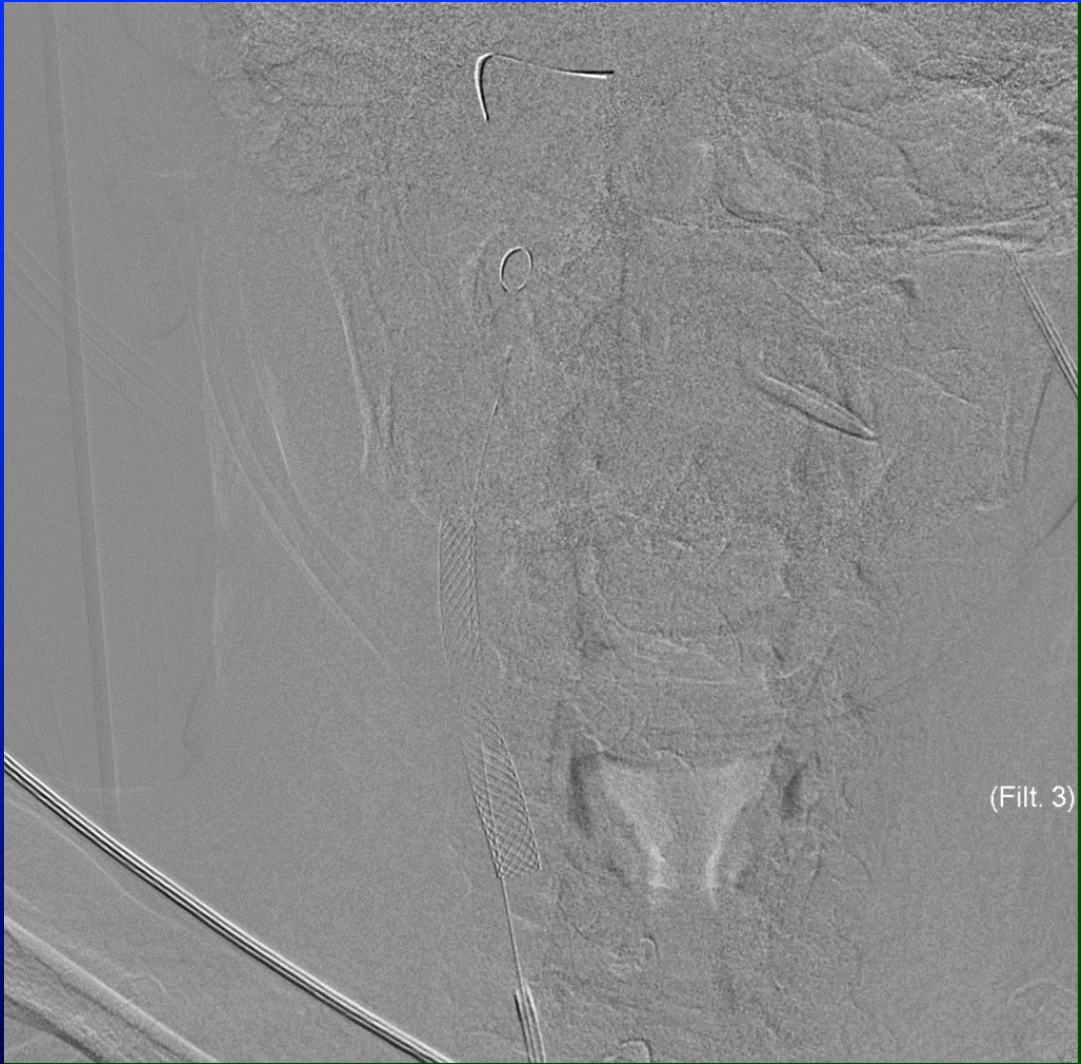(Filt. 3)

**Angio de repérage**

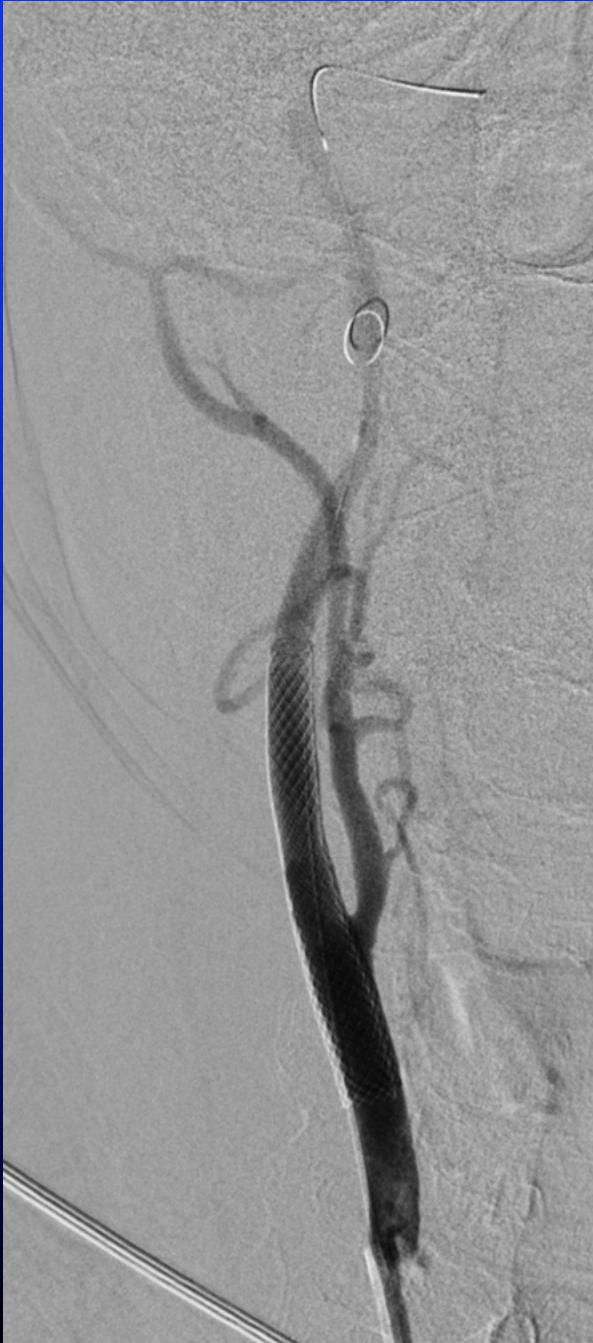

**Largage du Stent**

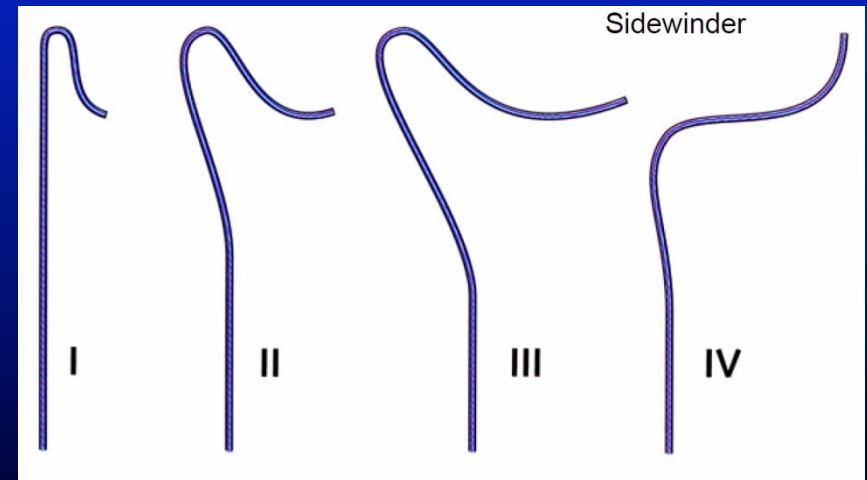
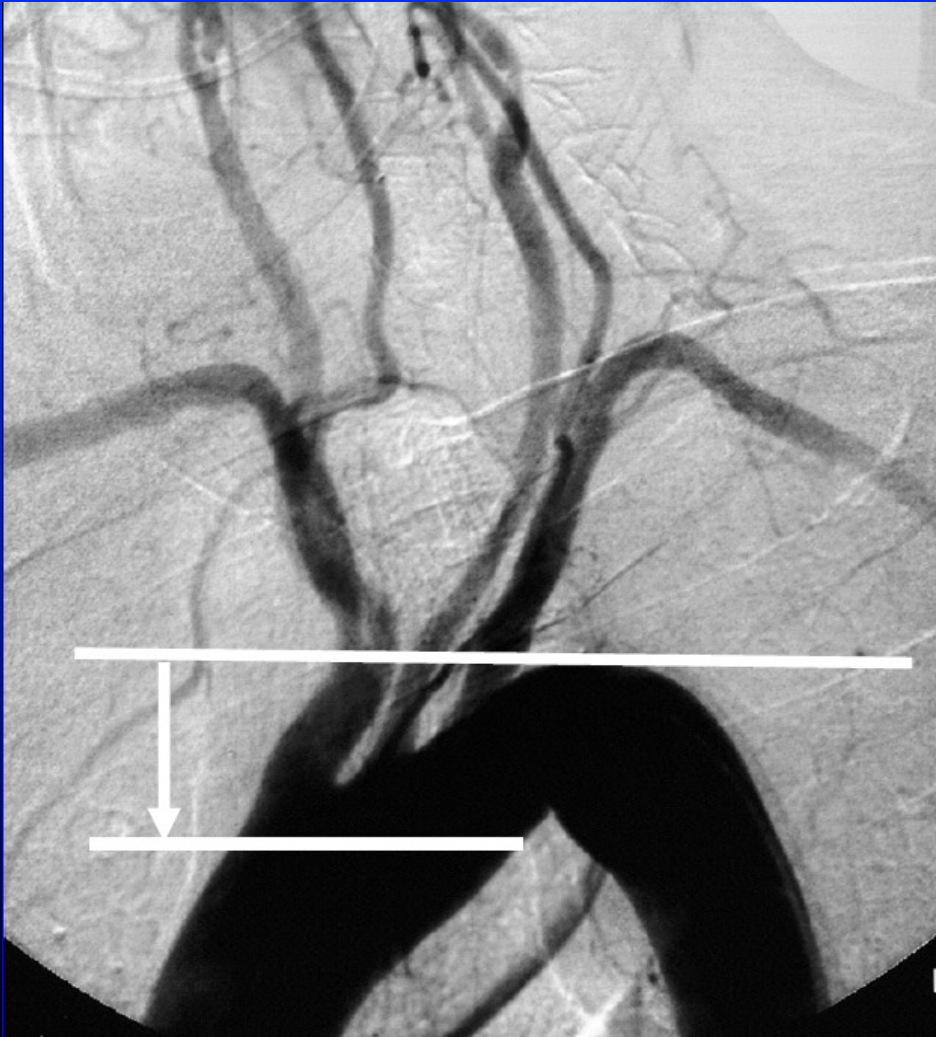




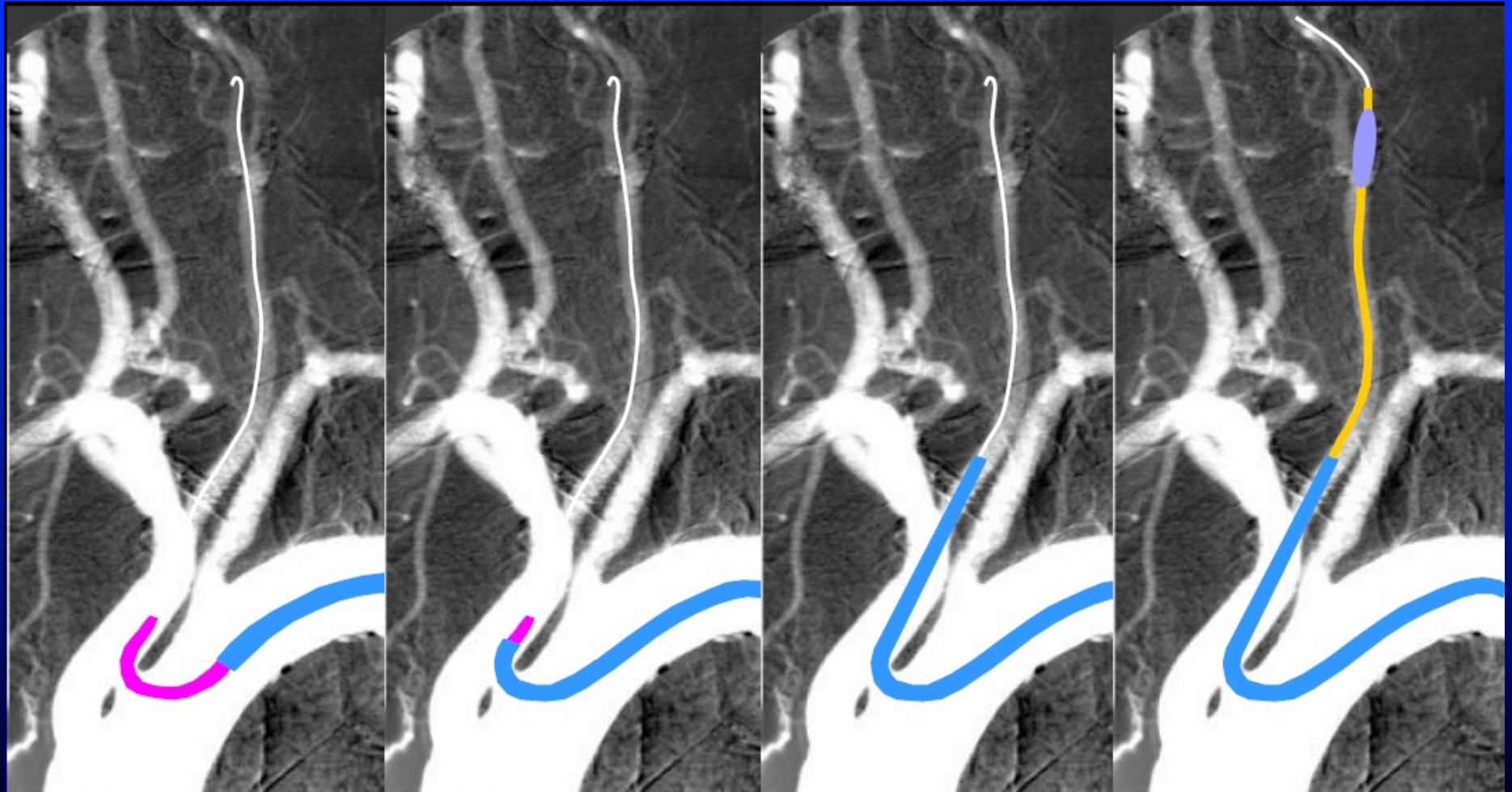(Filt. 3)



# L'anatomie la crosse aortique

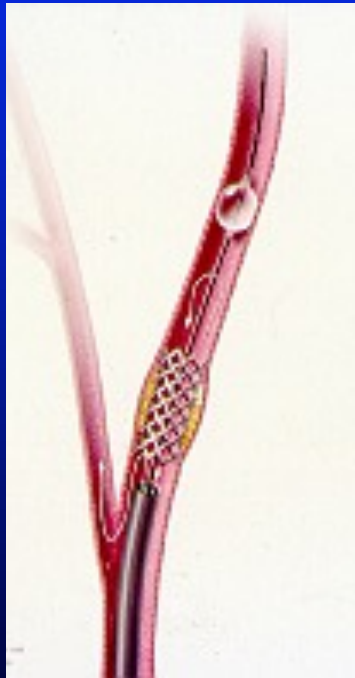

# Cathétérisme

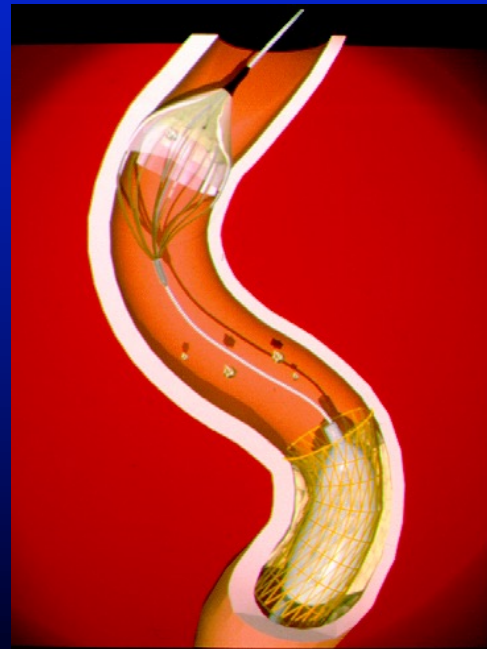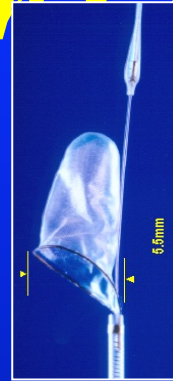


# La Protection Cérébrale

3 systèmes

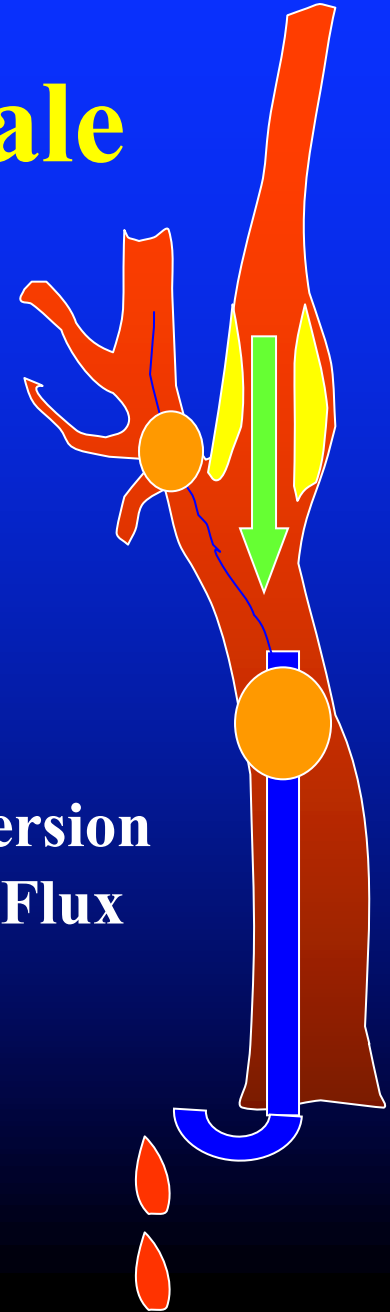


Occlusion distale

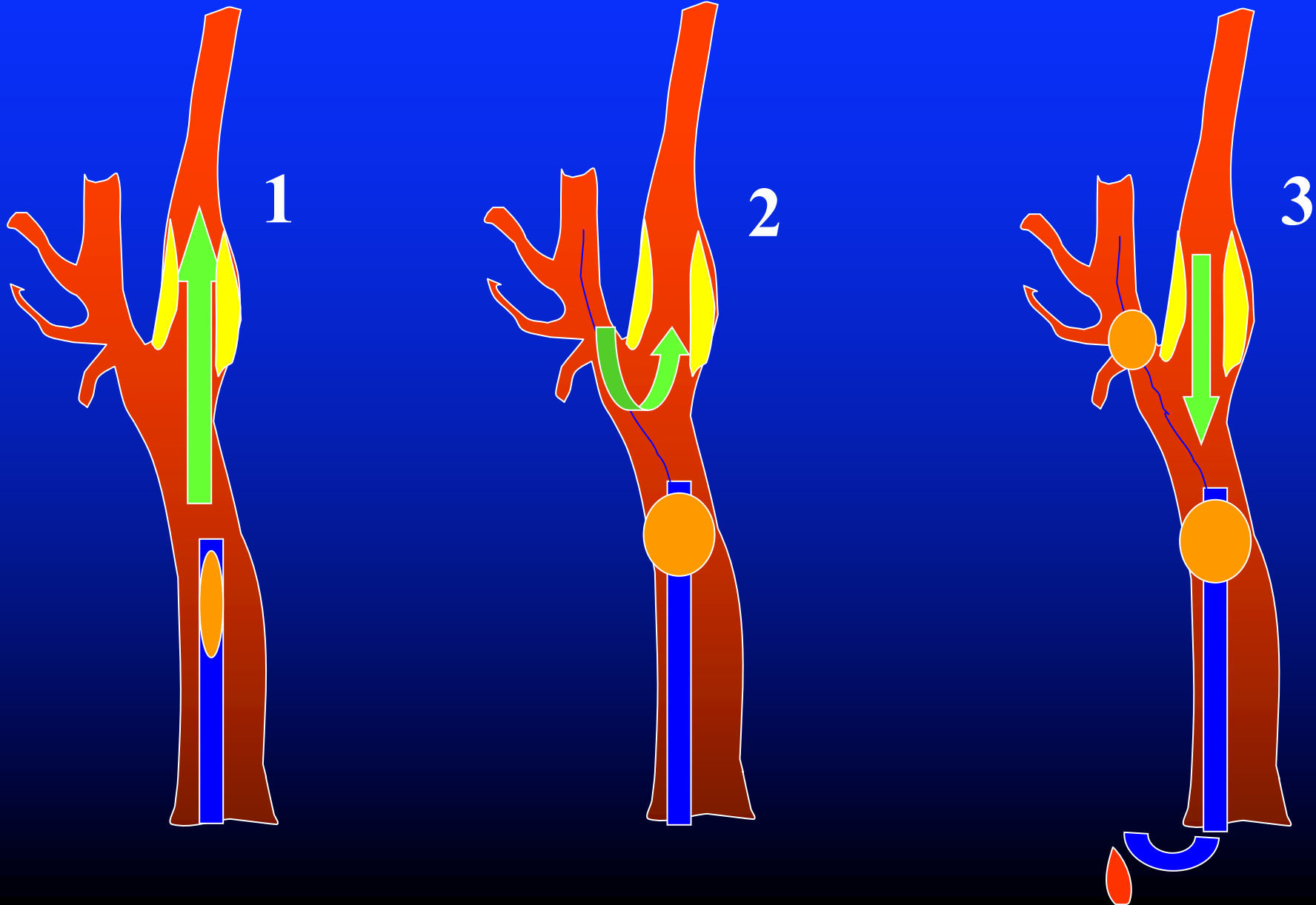


Les filtres

Inversion  
de Flux



# Inversion de Flux



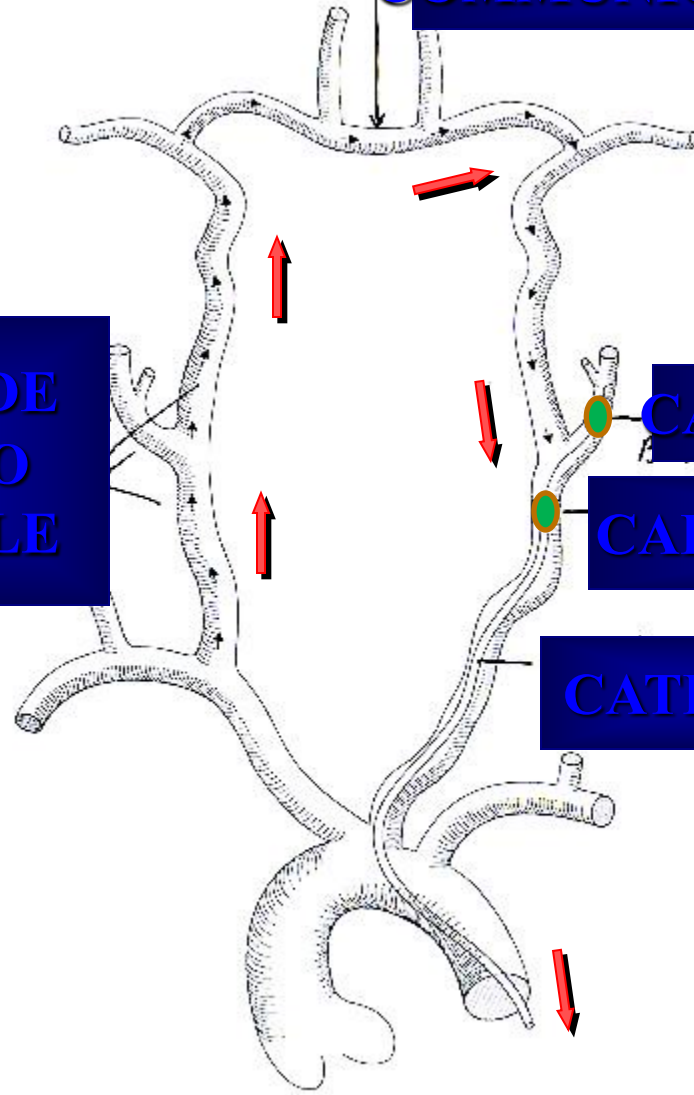
**COMMUNICANTE ANTERIEURE**

**CAROTIDE  
CONTRO  
LATERALE**

**CAROTIDE EXT OCCLUSE**

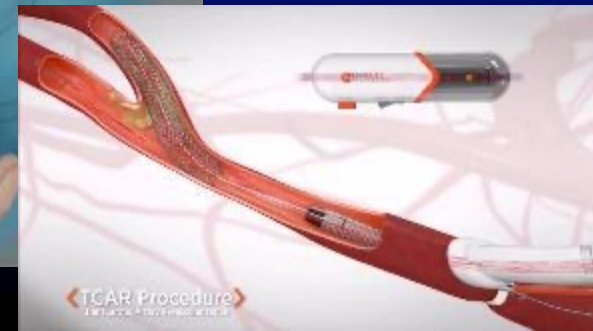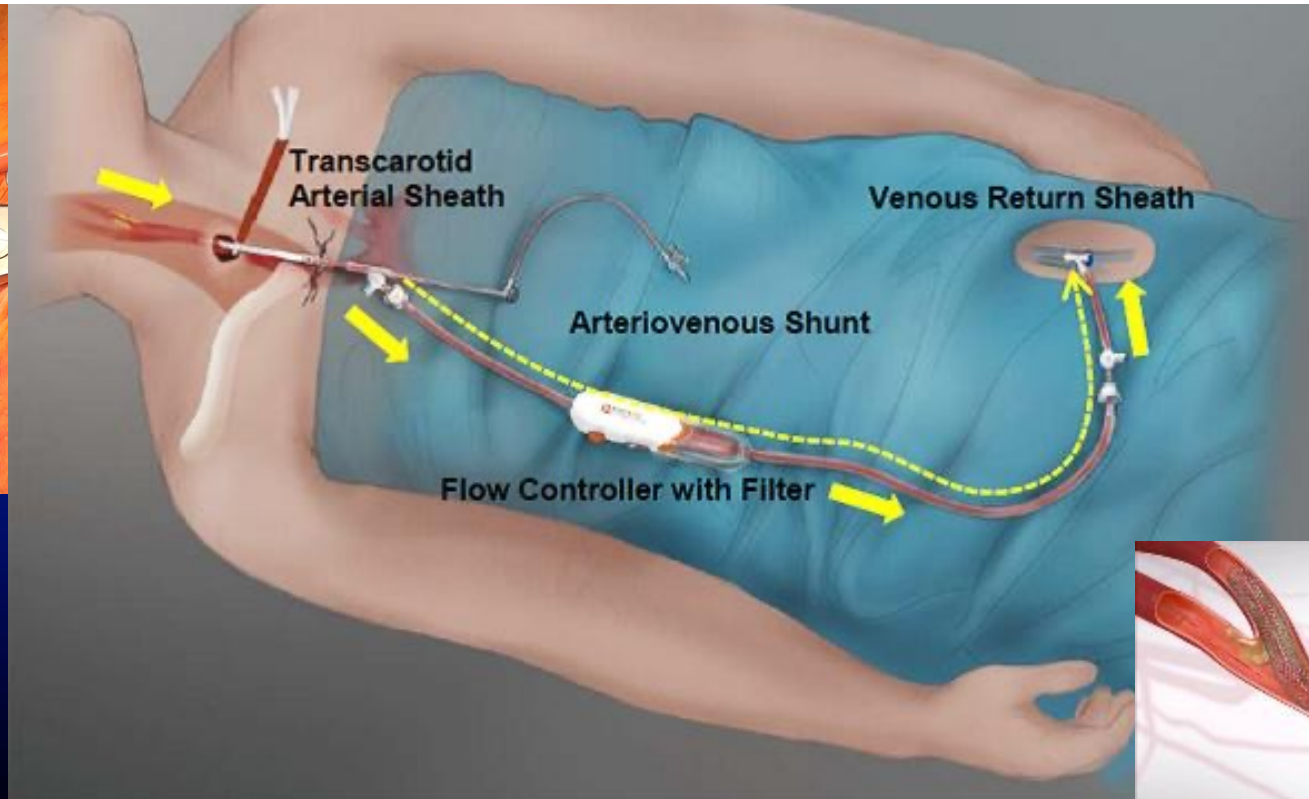
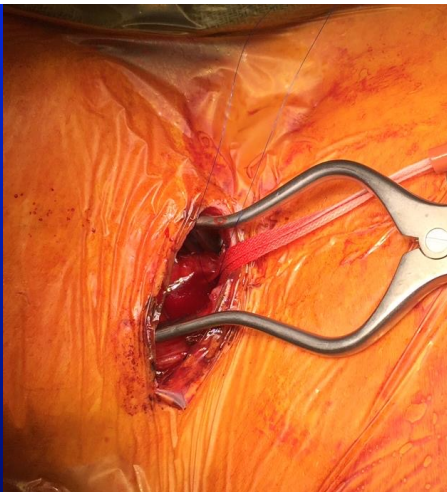
**CAROTIDE COMMUNE**

**CATHETER**



# The TCAR Revolution

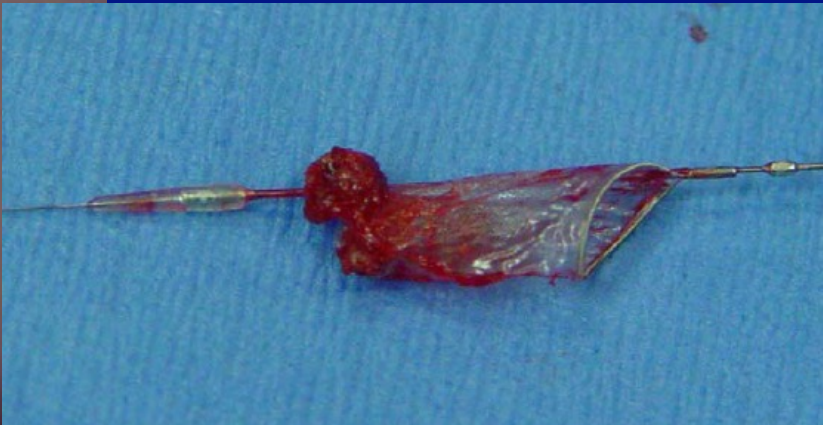

BY PETER A. SCHNEIDER, MD








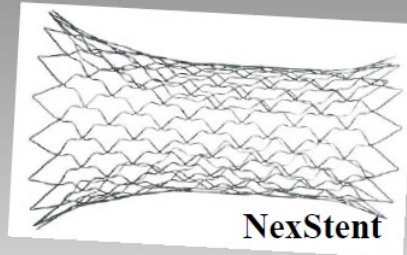
# Les Filtres



# Les Stents Carotidiens: Nitinol



Precise




NexStent



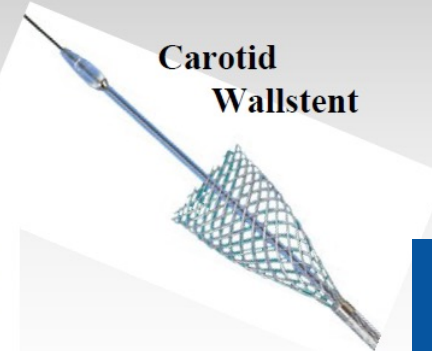
Exponent RX



Xact Carotid Stent




RX Acculink




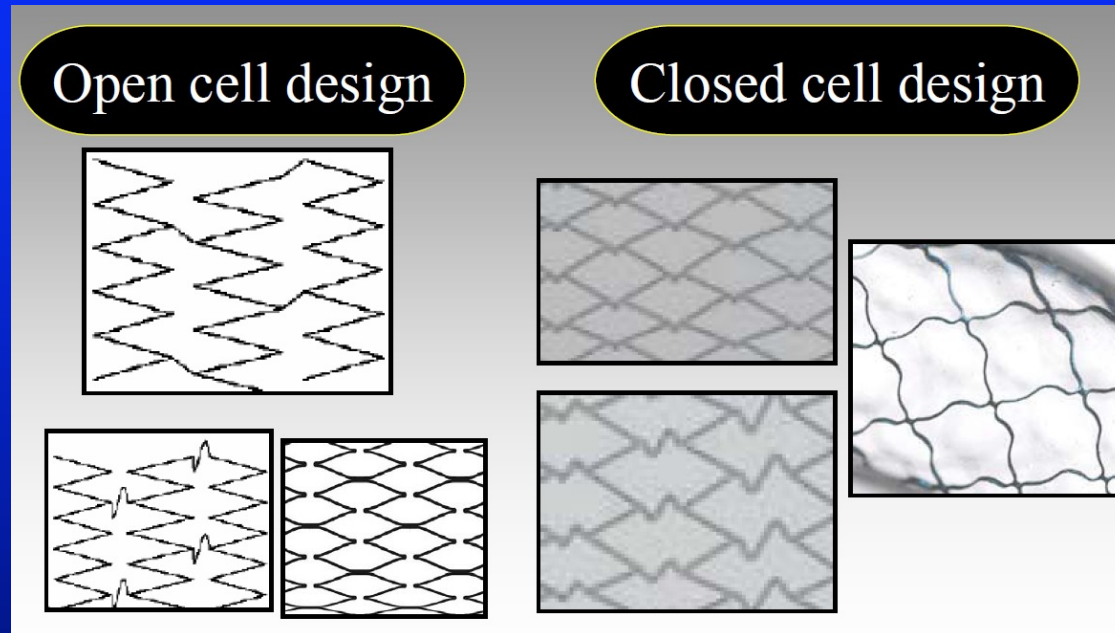
Carotid Wallstent



ProtégéRX



# Les Stents Carotidiens



Les cellules fermées seraient supérieures

# Pourquoi Dilater les Carotides ?

L'angioplastie doit être comparée au traitement de référence: la chirurgie

Le critère de jugement

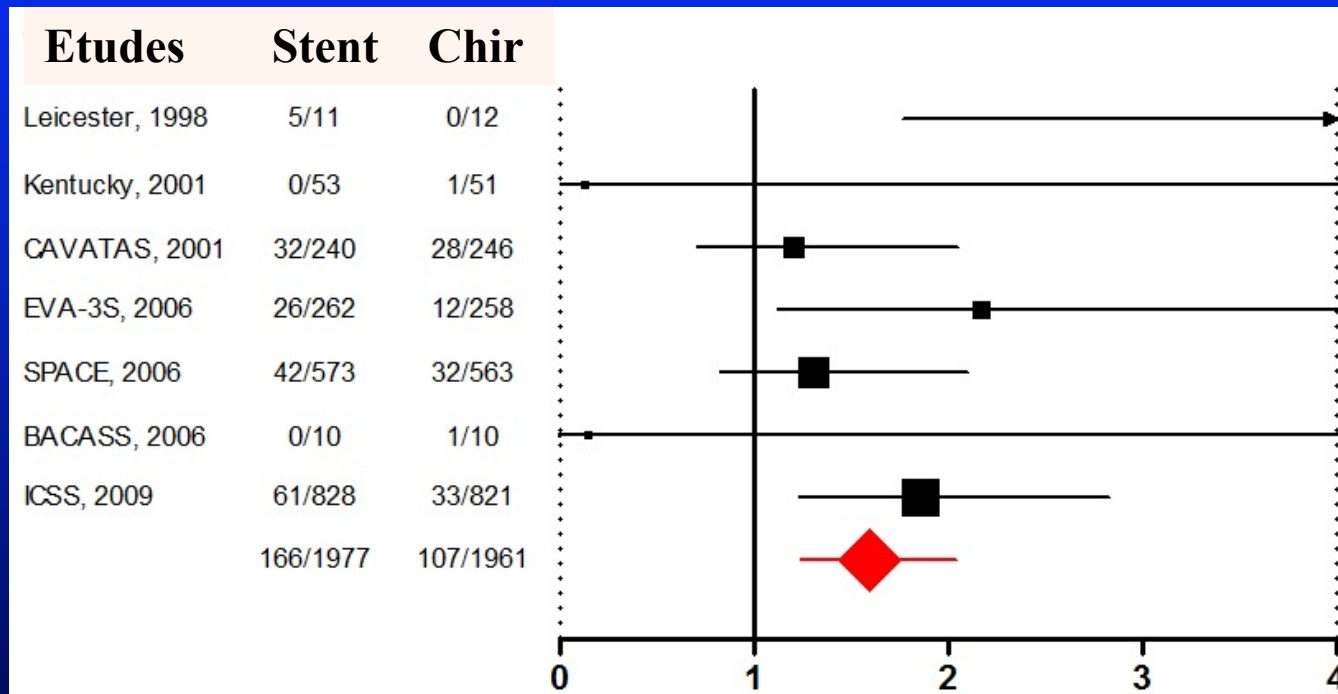
– AVC+DC=TCMM

– AVC+DC+IDM

# Le Patient Symptomatique

## Méta Analyse

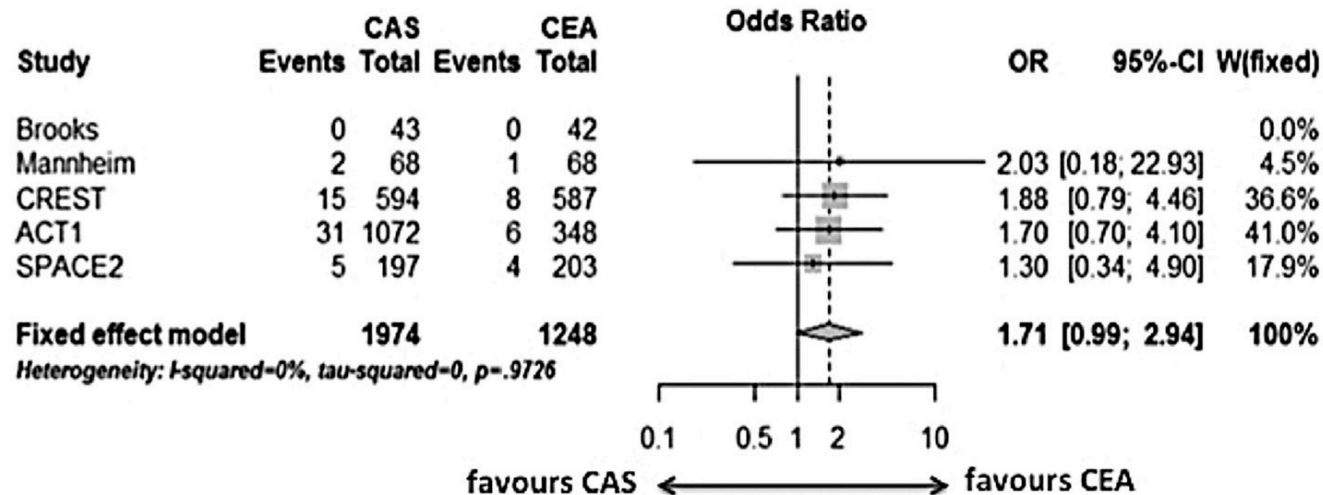
### TCMM+IDM à J30



*En faveur de la chirurgie*

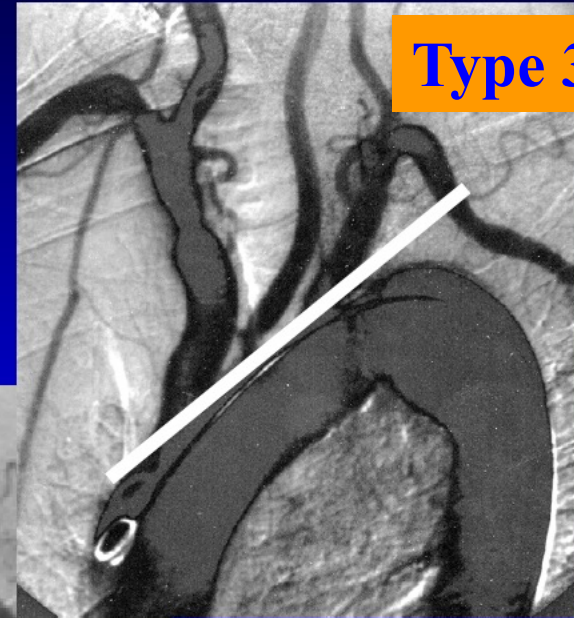
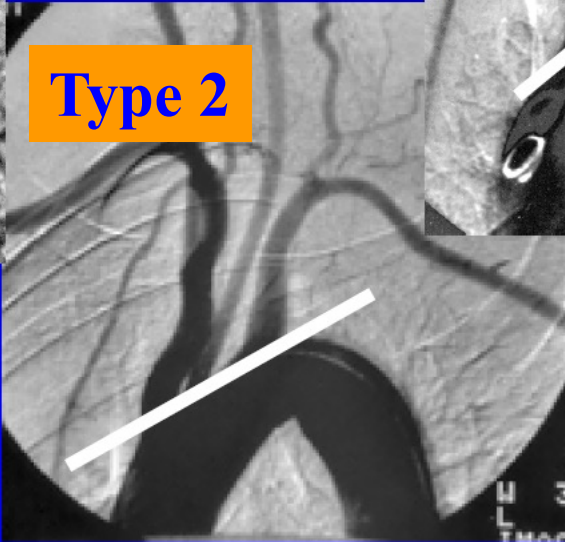
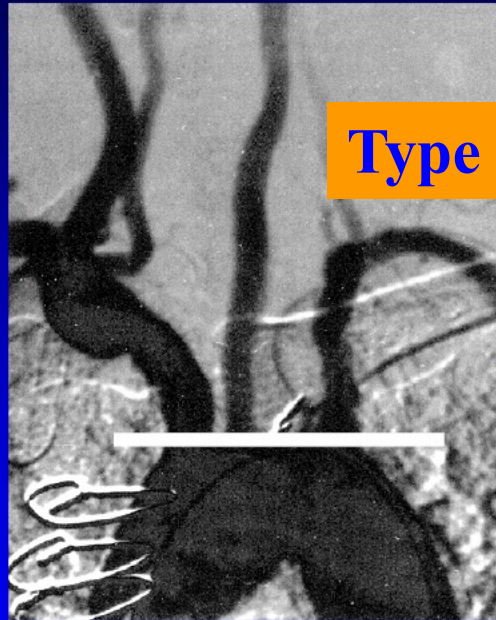
# Le patient ASYMPTOMATIQUE

Editor's Choice – Management of Atherosclerotic Carotid and Vertebral Artery Disease: 2017 Clinical Practice Guidelines of the European Society for Vascular Surgery (ESVS)



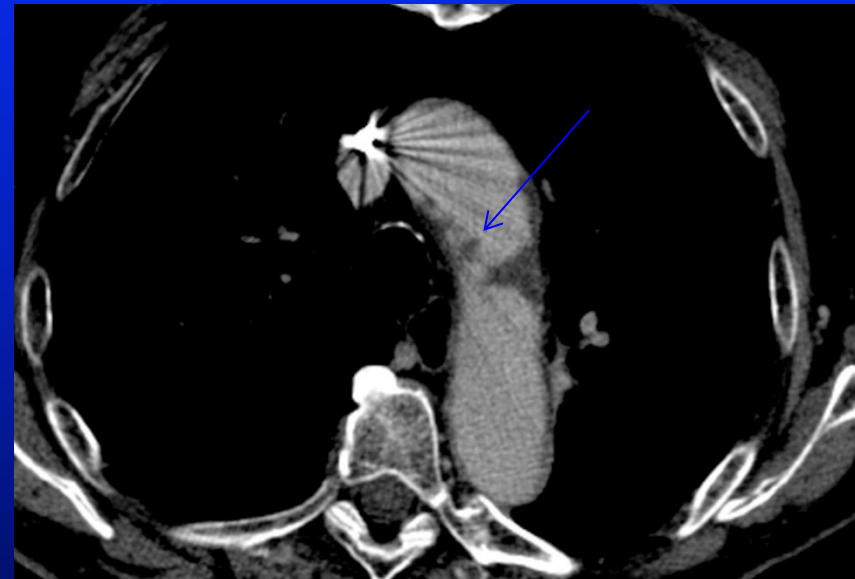
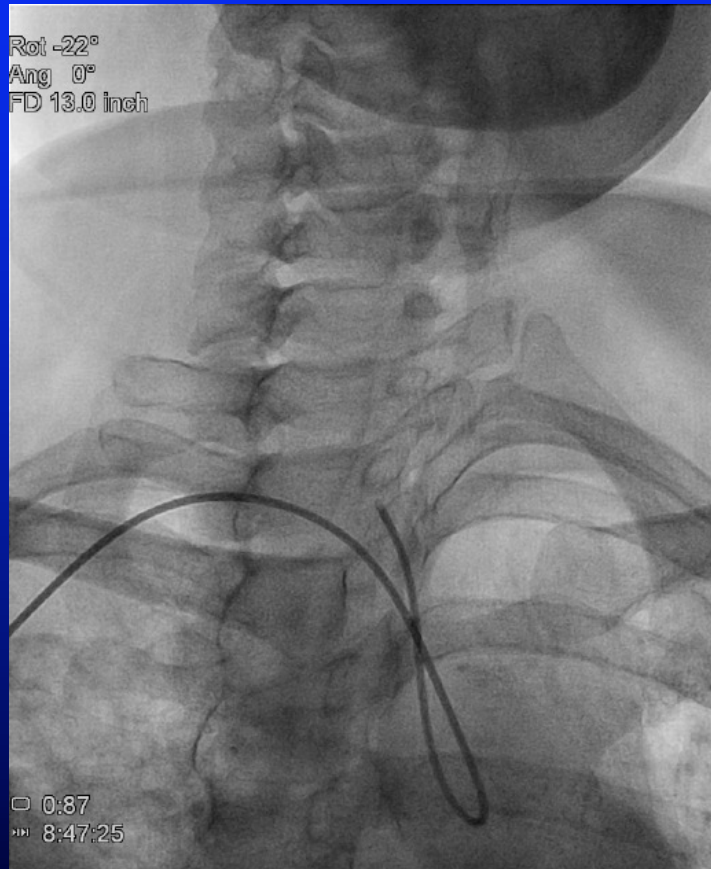
# **Les Cas Difficiles pour l'Angioplastie**

# la crosse aortique

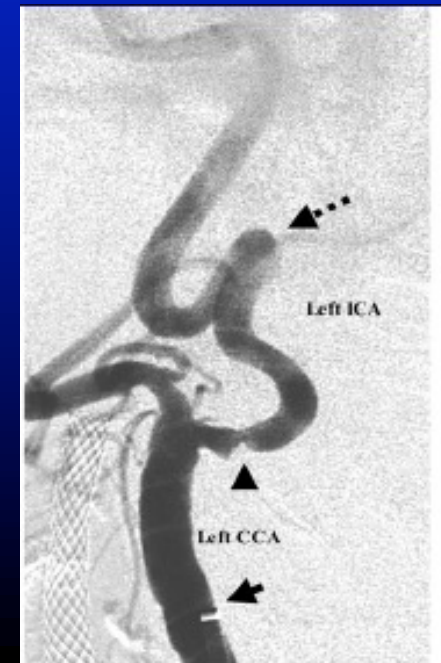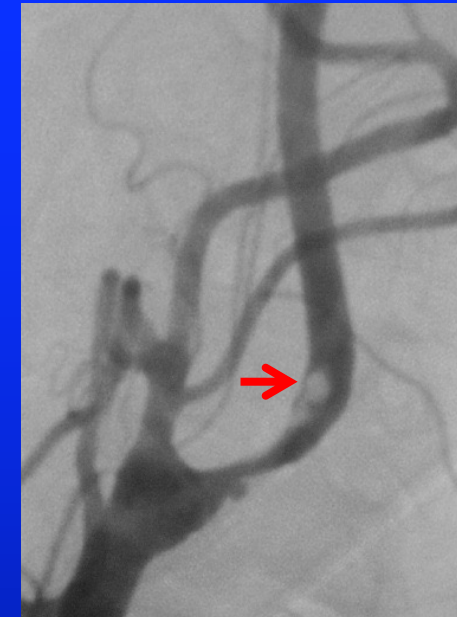

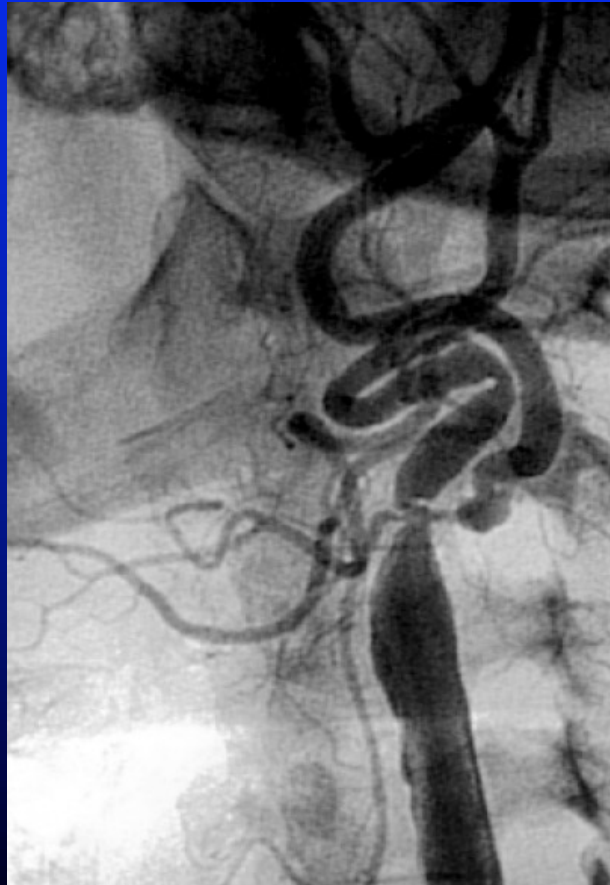
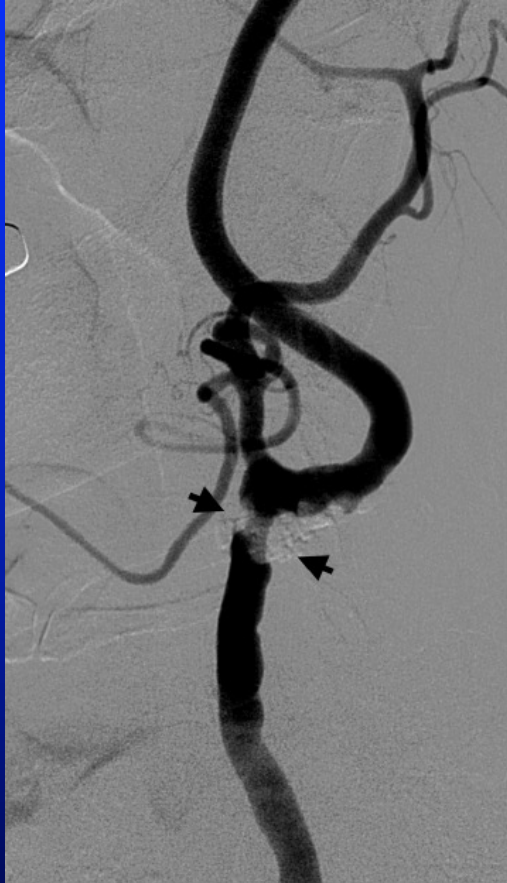

# La Crosse Aortique



# La Carotide



**JE VOUS REMERCIE**